

Paltov Y.V.,  
 Kryvko Y.Y.,  
 Fik V.B.,  
 Vilkhova I.V.,  
 Ivasivka Kh.P.,  
 Pankiv M.V.,  
 Voitsenko K.I.

*Danylo Halytskyi Lviv National Medical University, department of General Anatomy, Lviv, Ukraine*

## DYNAMICS OF THE ONSET OF PATHOLOGICAL CHANGES IN THE RETINAL LAYERS AT THE END OF THE FIRST WEEK OF OPIOID EXPOSURE

**Abstract.** *Objective of our work was to find out the fundamental issues relating to the dynamics of early changes in the reticular layers when the body was exposed to opioid. We conducted research on 15 sexually mature outbred male rats weighing 160 g, aged 4.5 months. The animals were injected intramuscularly with a medication nalbuphine, once a day in the same period of time (at 10-11 a.m.) for 7 days. The initial dose of nalbuphine was 0.212 mg / kg. By doing so we created conditions of chronic opioid effect. Histological specimens were prepared by the conventional method using dyes of hematoxylin, eosin and asan by Heidenhain method All animals were in vivarium conditions and the work that dealt with issues of maintenance, care, labeling and all other manipulations, was carried out in compliance with the provisions of the "European Convention for the Protection of Vertebrate Animals used for Experimental and other scientific purposes" [Strasbourg, 1985]. During the experimental study we established changes in the structure of the reticular layers after a week injection of opioid. As a result of our experimental opioid exposure during the first week we recorded some pathological changes, which manifested themselves in the appearance of the initial effects of vacuolar degeneration of the pigment epithelium, signs of microcystic degeneration of outer reticular layer with symptoms of vacuolar degeneration of retinal ganglion cells.*

**Key words:** *microstructure, layers, retina, opioid, early stages, rats.*

**Introduction.** The results of the paper correspond to the research plan of Danylo Halytskyi Lviv National Medical University and are a part of the scientific - research theme of the department of General Anatomy "Structural organization of angioarchitectonics and anthropometric features of organs in intra and extrauterine development period, influenced by exo - and endopathogenic factors" (the number of state registration 0115U000041) for 2015 – 2019.

Today 100 million addicts have been registered all over the world [1, 2], including 2,897 people in Ukraine, who, according to statistical data of the Ministry of Health, use opioid drugs uncontrollably [3]. Prolonged use of surrogate medication opioids, according to

the literature, contributes to pathological changes in a number of organs. In particular, there is a number of publications that cover the processes of pathological manifestations in the cardiovascular system [1, 4, 5, 6, 7]. Some authors also covered the problem of changes in the iridocorneal angle as well as the pathotransformation of optic nerves resulting from toxic damage by opioids [8, 9]. In the available literature we found rare and disconnected data on pathological changes of the vision in particular those, concerning the retina.

Neurovascular factor creates a base for pathogenesis of opioid retinopathies. To date there are no studies that can answer the question: what is affected primarily – the layers

of the retina, due to trophic disorders, or the retinal vessels as an object of neurotrophic effect.

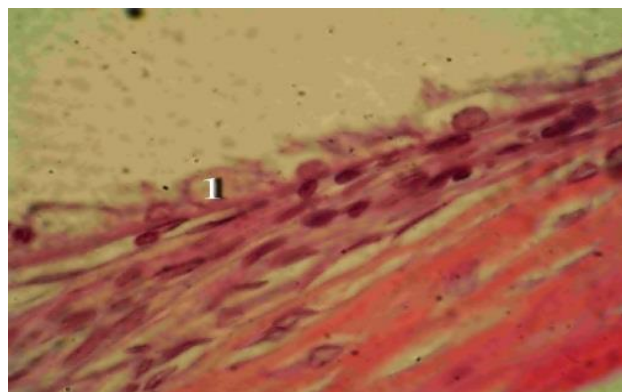
Therefore, I believe that this study is important both in terms of experimental and morphological studies, and from a practical point of view.

**Materials and methods.** We conducted our research on 15 sexually mature outbred male rats weighing 160 g and aged 4.5 months. The animals were injected intramuscularly with a medication nalbuphine, once a day in the same period of time (at 10-11 a.m.) for 7 days. The initial dose of nalbuphine was 0.212 mg / kg. By doing so, we created conditions of chronic opioid effect. [10].

The animals were divided into 2 groups. The first group of animals received nalbuphine for 7 days, followed by a collection of experimental material (the end of the 1st week of experimental opioid exposure); the 2nd group was a control one that received injections of saline intramuscularly in the same period of time (10-11 a.m.). All animals were in vivarium conditions and the work that dealt with issues of maintenance, care, labeling and all other manipulations, was carried out in compliance with the provisions of the "European Convention for the Protection of Vertebrate Animals used for Experimental and other scientific purposes" [Strasbourg, 1985], "General ethics of animal experimentation, approved the first National Congress of bioethics [Kyiv, 2001]. Law of Ukraine № 3447 - IV «On protection of animals against cruel treatment." Commission on bioethics of Danylo Halytskyi Lviv National Medical University revealed that the research met the ethical requirements under MHP of Ukraine number 231 of 01. 11. 2000 (protocol № 10 dated 26.12. 2011.) (protocol № 2 on February 20, 2012). Before taking biopsy material the animal were put to sleep by intraperitoneal administration of thiopental (at 25 mg / 1 kg). As a material for microstructure studies we used rats' eyeballs obtained by postmortem enucleation with further consideration of conservation of topographic correlation of eye membranes by making histological sections 5-7 microns thick. Histological specimens were prepared by the

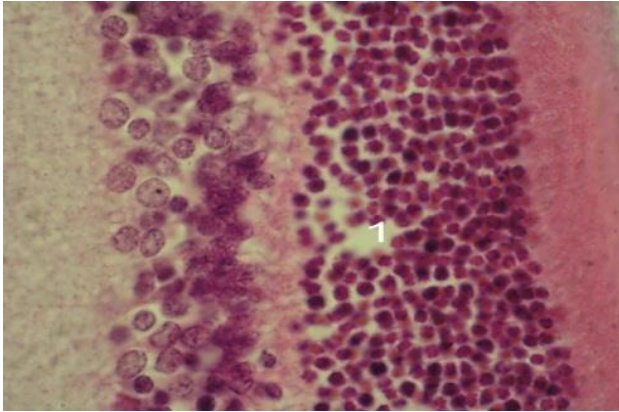
conventional method using dyes of hematoxylin, eosin and asan by Heidenhain method [11]. Microscopic studies and photography of the specimens were performed with a microscope IBI – 1 and a digital camera Nikon D 3100.

**Results and discussion.** As a result of our microscopic examination of the structural layers of the rats' retina after a week of the experiment the retinal pigment epithelium in the experimental animals in the interval from the optic nerve to the dentate line is discontinuous. In some areas of the retina the pigment epithelium consists of elongated cells which are arranged with their longitudinal axis parallel to the basement membrane and are firmly connected to the inner layer of the latter. We found some spaces in some areas of the retina where the epithelial layer is absent. In other parts of the retina we found epithelial cells with swollen cytoplasm which contains semitransparent vacuoles (vacuolar degeneration), as shown in Fig. 1. The nuclei of such epithelial cells are usually saved and located closer to the basal pole. The basement membrane is integral, homogeneous and weakly basophilic. In the lumen of the capillaries of the choroid there are some signs of stagnation and plethora. Cytoplasmic processes of photoreceptor cells lie somewhat loose and sparse in the layer of rods and cones. There were not any structural changes in the outer boundary layer at this stage of the experiment. The outer nuclear layer sometimes contains irregularly shaped or pyknotic nuclei. In some parts there are significant spaces between the nuclei, as shown in Fig. 2. In the disk of optic



*Fig 1. Rat's retina a week after a daily opioid injection. Stained with hematoxylin and eosin. Magn.: x 1000. 1– vacuolization of pigment epithelium*

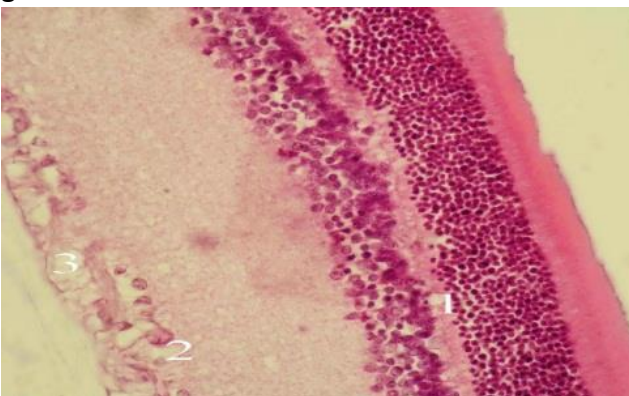
nerve area the outer nuclear layer is thinner, the spaces between the nuclei are slightly larger, the number of rows of nuclei is 5-8. In the area of the dentate line the outer nuclear layer is also thinner, it contains 3-5 rows of nuclei. The nuclei of photoreceptor cells move into the outer reticular layer in some places. Nuclei of bipolar cells sometimes occur in the external reticular layer.



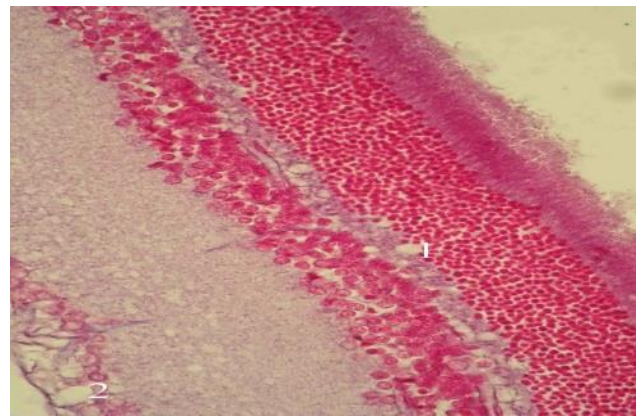
*Fig. 2. Rat's retina a week after opioid injection. Stained with asan. Magn.: x 1000. 1 – nuclear-free areas in the outer nuclear layer.*

Quite often clear spaces of the basic substance occur in the outer reticular layer, often forming microcysts (microcystic degeneration), as shown in Fig. 3 and Fig. 4. In some areas microcysts reach the inner nuclear layer, and sometimes they contact with the outer nuclear layer.

The inner nuclear layer within the specified term of the experiment has structural organization similar to the control one, but the ground substance around some nuclei of the



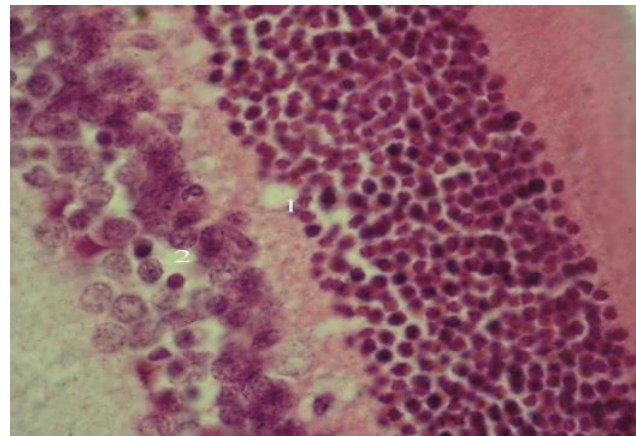
*Fig. 3. Rat's retina a week after opioid injection. Stained with hematoxylin and eosin. Magn.: x 400. 1– microcystic degeneration of the outer reticular layer; 2 – pericellular swelling of ganglion cells; 3 – microcystic degeneration of the nerve fiber layer.*



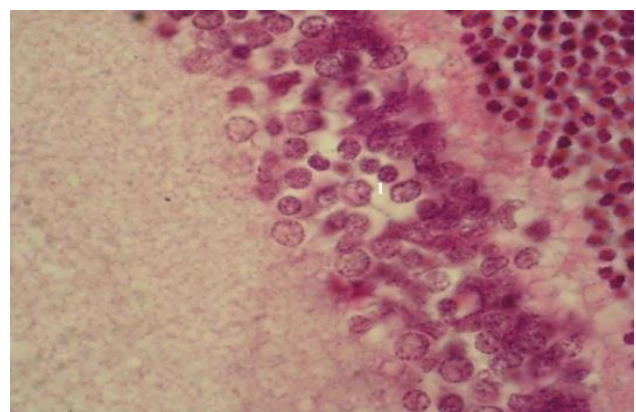
*Fig. 4 Rat's retina a week after opioid injection. Stained with asan. Magn: x 400. 1– microcystic cavities in the outer reticular layer; 2– microcystic cavities of the nerve fiber layer.*

bipolar cells is cleared, there are some signs of a slight pericellular swelling, as shown in Fig. 5 and Fig. 6. In some places the nuclei of amacrine cells immersed in the inner reticular layer.

There were not any pathological changes in



*Fig. 5. Rat's retina a week after opioid injection. Stained with asan. Magn.: x 1000. 1– microcystic cavities in the outer reticular layer; 2– Cleared areas in the inner nuclear layer.*



*Fig. 6. Rat's retina a week after opioid injection. Stained with asan. Magn.: x 1000. 1– pericellular swelling in the inner nuclear layer.*



the structure of the inner reticular layer within the specified period of the experiment. In some cells of the ganglionic layer the nuclear center is cleared, its chromatin is located near the shell of the nucleus. The cytoplasm of some ganglionic cells is cleared and contains vacuoles. The endothelium of some vessels, located on the edge of the layer of nerve fibers is slightly swollen. The ground substance of the nerve fiber layer is often cleared, containing microcysts in such areas, as shown in Fig. 7. This layer becomes much broader towards the optic nerve and contains extensively shaded thick purple fibers when stained with asan. There were not any structural changes in the inner boundary layer at the end of the first week with opioid exposure.

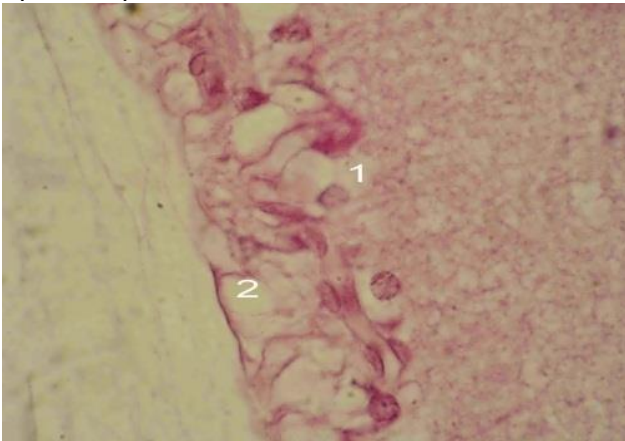


Fig. 7 Rat's retina a week after a daily opioid injection. Stained with hematoxylin and eosin.

Magn.: x 1000. 1– vacuolization of some ganglionic cells; 2– microcystic degeneration of nerve fibers.

**Conclusions.** As a result of our experimental opioid exposure, during the first week we recorded some pathological changes, which manifested themselves in the appearance of the initial effects of vacuolar degeneration of the pigment epithelium, signs of microcystic degeneration of outer reticular layer with symptoms of vacuolar degeneration of retinal ganglion cells.

**Perspectives of further investigations.** The pathomorphological manifestations in the layers of the retina during experimental opioid exposure that have been found, can serve as a morphologic basis for further study of the manifestations of opioid retinopathy in the experiment. Our results can later be used for comparative characteristics concerning the dynamics of pathological changes in the layers of

the retina in cases of short and long term exposure to low doses of opioids.

#### References:

1. Раєцька Л.В. Тенденції поширення наркоманії в Україні /Л.В. Раєцька // *Боротьба з організованою злочинністю і корупцією.*– 2008.– С. 318.
2. *Official Records of the Economic and Social Council Fourteenth Session, / Supplement №1 (E/2331).*– 12 p.
3. Адрашкин А.П. Роль сердечно – сосудистой системы в танатогенезе у опийных наркоманов второй стадии / А.П. Адрашкин, И. В. Саломатин, Б.Ф. Мурашов [и др.] // – М.,– 2003.– С. 18.
4. Бунин Я.А. Микроциркуляция глаза / Я.А. Бунин, Л.А. Кацнельсон, А.А. Яковлев // – М.: Медицина, – 1984. – 175 с.
5. Рохлина М.Л. Клинико – социальные последствия наркоманий / М.Л. Рохлина, А.А. Козлов, И.Я. Каплан // *Вопросы наркологии.*– 1998.– № 1.– С. 11-20.
6. Сичкориз Л.М. Морфометрический анализ ангиоархитектоники ишемизированной радужки глаза / Л.М. Сичкориз, Л.Р. Матешук, М.П. Закрута // *Проблемы патологии в эксперименте и клинике.* – 1989.– Т. 11.– С. 75.
7. Шабанов П.Д. Биология алкоголизма / П.Д. Шабанов, С.Ю. Калишевич // – С. Пб.,– 1998.– 271 с.
8. Якимів Н.Я. Мікроструктурна характеристика райдужно – рогівкового кута очного яблука щурів при опіоїдному впливі / Н.Я. Якимів, Ю.Я. Кривко // *Світ медицини та біології.*– 2013.– №4.– С. 120-124.
9. Новицький І.Я. Токсичне ураження зорових нервів внаслідок тривалого прийому левоміцетину на тлі наркотичної залежності від кодтерпіну / І.Я. Новицький, Н.Я. Якимів, О.М. Єрохова, О.О. Король, М.І. Новицький, О.С. Фітькало // *Офтальмологический журнал.*– 2012.– № 3.– С. 43-45.
10. Патент №76565 Україна. Спосіб моделювання хронічного опіоїдного впливу/ Є.В. Пальтов, В.Б. Фік, І.В. Вільхова, Р.М. Онисько, О.С. Фітькало, Ю.Я. Кривко; заявник і патентовласник Львівський національний медичний університет імені Данила Галицького . – опубл. 10. 01. 2013, Бюл. №1.
11. Б.Ромейс *Микроскопическая техника.* – М.: Медицина, 1953.–с. 71-72.