ISSN 2509-4327 (print)
ISSN 2510-4780 (online)

Deutscher Wissenschaftsherold
German Science Herald

№ 3/2017

Die Zeitschrift „Deutscher Wissenschaftsherold" ist eine Veröffentlichung mit dem Ziel ein breites Spektrum der Wissenschaft allgemeinverständlich darzustellen. Die Redaktionsleitung versteht sich als Vermittler zwischen Wissenschaftlern und Lesern. Durch die populärwissenschaftliche Bearbeitung wird es möglich unseren Lesern neue wissenschaftliche Leistungen am besten und vollständigsten zu vermitteln. Es werden Untersuchungen, Analysen, Vorlesungen, kurze Berichte und aktuelle Fragen der modernen Wissenschaft veröffentlicht.

Impressum
Deutscher Wissenschaftsherold – German Science Herald
Wissenschaftliche Zeitschrift
Herausgeber:
InterGING
Sonnenbrink 20
31789 Hameln, Germany
Inhaber: Marina Kisiliuk
Tel.: + 49 51519191533
Fax.:+ 49 5151 919 2560
Email: info@dwherold.de
Internet:www.dwherold.de
Chefredakeur/Editor-in-chief:
Marina Kisiliuk
Korrektur:
O. Champela
Gestaltung:
N. Gavrilets

Auflage: № 3 2017 (August) – 23
Redaktionsschluss August, 2017
Erscheint vierteljährlich
Editorial office: InterGING
Sonnenbrink 20
31789 Hameln, Germany
Tel.: + 49 51519191533
Fax.:+ 49 5151 919 2560
Email: info@dwherold.de
Deutscher Wissenschaftsherold - German Science Herald is an international, German/English language, peer-reviewed, quarterly published journal.
№ 3 2017
Passed in press in August 2017
Druck: WIRmachenDRUCK GmbH
Mühlbachstr. 7
71522 Backnang
Deutschland

INDEXING: Google Scolar, WorldCat, InfoBase Index, Journal Index, Citefactor, International Scientific Indexing, JIFACTOR, Scientific Indexing Services, International Institute of Organized Research.

http://miar.ub.edu/issn/2509-4327

REDAKTIONSKOLLEGIUM / INTERNATIONAL EDITORIAL BOARD:

Lists of references are given according to the Vancuver style

DDC-UDC 616.61-085.835.3:611.6:612.46.15]-092.9 DOI:10.19221/2017320

Fedoruk O.S.,
Doctor of Medical Sciences (MD), Professor, Department of Urology and Neurosurgery, Higher State Educational Establishment of Ukraine "Bukovinian State Medical University", Chernivtsi, Ukraine, a.fed@mail.ru
Vizniuk V.V.
Assistant of the Department of Urology and Neurosurgery,of Higher State Educational Establishment of Ukraine "Bukovinian State Medical University", Chernivtsi, Ukraine, viznyuk_v@ukr.net

ANALYSIS OF MORPHOLOGICAL EXAMINATION OF ANIMAL KIDNEYS UNDER CONDITIONS OF OZONE THERAPY

Abstract. *The results of experimental morphological studies of kidneys in case of acute pyelonephritis and therapeutic effect of ozone therapy in the experiment conducted on rats have been analyzed. Changes in the kidney tissues most frequently damaged in case of complicated acute pyelonephritis have been determined. The reasonability of ozone therapy application in the treatment of infectious-inflammatory diseases of the kidneys is evidenced, and its addition to postoperative therapeutic complex is considered to be the most reasonable.*
Key words: *morphofunctional kidney changes, ozone therapy, urolithiasis.*

Introduction. Nowadays the tactics of management of patients suffering from urolithiasis complicated with pyelonephritis does not always keep to the principles of detection of ureter occlusion and optimal diagnostic algorithm is not available. Its elaboration and further introduction into clinical practice will enable to make a comprehensive diagnostics of complication available as quick as possible keeping to the principle of priority in treatment of patients with application of distant shock-wave lithotripsy and ozone therapy [1, 7].

The character of pathological changes occurring in case of acute pyelonephritis is in general examined and widely presented in literature [2]. However, there are a number of regularities that should be noted in the context of comparison of clinical signs with the results of experimental studies of morphological groups where ozone therapy was applied as a therapeutic method. In this case changes occurring in different areas of the nephron and renal interstitial tissue should be isolated.

Certain evidences are available concerning favourable ozone effect on the damaged tissue structures after development of acute processes, the efficacy of ozone therapy method to renew the kidney functional state is indicated, certain recommendations are obtained concerning the choice of a rational range of ozone effective doses, detoxicative effects of ozone therapy in treatment of acute infectious-inflammatory complications are determined [3, 6].

Since the investigation of morphofunctional condition and ultrastructural mechanisms of acute pyelonephritis in clinical conditions is next to impossible to be performed completely we have conducted experimental studies in simulating the disease in the experiment.

Objective: to assess experimentally the effect of ozone therapy on the morphofunctional indices of the kidneys with underlying pyelonephritis.

Materials and methods. Experimental acute pyelonephritis was modeled on 33 mature rats. Inflammatory process was simulated in the form of pyelonephritis according to methodical approaches developed by P.I. Remezov (1960).

The method of experimental modeling of acute pyelonephritis in animals included surgery imitating upper urinary tract obstruction followed by infection with the agents of acute pyelonephritis (E.Coli - $2,5*10^8$CFU/ml).

Results and discussion. The studies conducted enable to solve the tasks of the experiment from the positions of metabolic effects of ozone therapy. Generated dystrophic and necrotic changes in the kidney structure before ozone therapy are irreversible, therefore the effect of ozone therapy is assessed as a positive one preventing further development of acute pyelonephritis.

Morphological changes of the kidney tissues after development of acute experimental

pyelonephritis and its treatment by means of parenteral introduction of ozonized solutions (ozone concentration in the solution 500 mcg/L) in the postoperative period differ much from the morphological manifestation of acute pyelonephritis of the control group of animals. Since the effect of conducted ozone therapy enables to eliminate hypoxia of the kidney tissue quickly, and as a result to activate metabolism in the kidney, it produces a positive effect on the course of the inflammatory process in the kidney.

On the 3rd day of acute experimental pyelonephritis and its treatment with parenteral introduction of ozonized solutions practically complete inhibition of inflammatory process is determined histologically, which is seen in elimination of an inflammatory infiltrate and interstitial swelling in the kidney medulla (Fig. 1).

On the 10th day of the experiment under conditions of correction of experimental pyelonephritis by means of ozonized solution use a relative normalization of the cortical substance structure is observed.

Similar reorganization of structural components is found in the medullar substance of the organ. Direct tubules are moderately widened, epithelial cells are clearly outlined, only in separate tubules destruction of the cellular cytoplasm is found (Fig. 2, Fig. 3).

Conducted electron microscopic examinations of the kidney cortical substance in this group of experimental animals on the 3rd day of the experiment have detected decrease of destructive

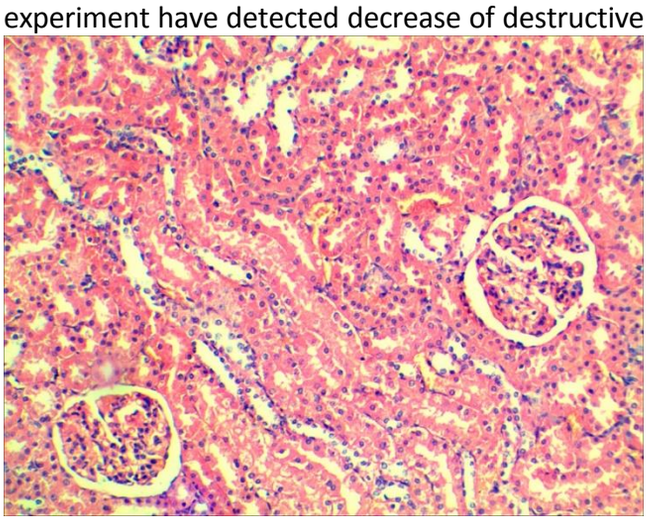

Fig. 1. Microscopic condition of the kidney cortical substance in animals on the 3rd day after experimental pyelonephritis and application of ozonized solutions. Hypertrophic kidney bodies with a clear structural organization of glomeruli, well structured tubules. Staining with hematoxylin and eosin. x 200

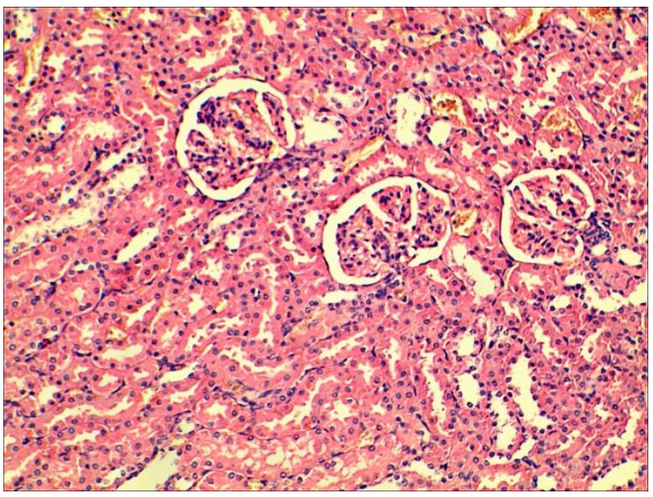

Fig. 2. Microscopic condition of the cortical substance in the animal kidney on the 10th day after experimental pyelonephritis and application of ozonized solutions. The kidney body with moderately enlarged capsule space, partially changed twisting tubules. Staining with hematoxylin and eosin. x 200

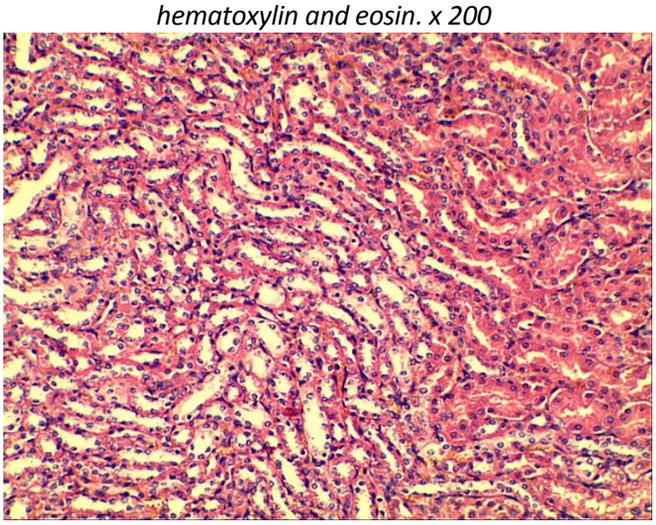

Fig. 3. Microscopic condition of the cortical substance in the animal kidney on the 10th day after experimental pyelonephritis and application of ozonized solutions. Direct tubules are moderately widened and epithelial cells are clearly outlined. x 200.

changes of its components.

The blood capillaries of the vascular glomerulus in the kidney bodies and capillaries of the peritubular network are moderately widened. They include blood corpuscles, erythrocytes prevail. Endotheliocytes contain nucleli of an elongated shape with prevalent euchromatin in the karyoplasm. The membranes of the nuclear layer are clearly outlined. The cytoplasm of endotheliocytes, podocytes and cytotrabeculae is swollen and lucid in some places. Fenestration is well seen in the cytoplasmic areas of the endothelial cells. The basal membrane is clearly outlined and preserves three-layer structure (Fig. 4).

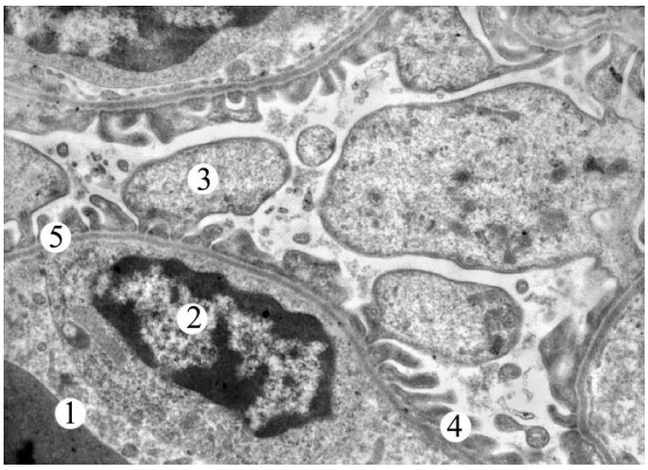

Fig. 4. Ultrastructural condition of the kidney body components of animals on the 3rd day after experimental pyelonephritis and application of ozonized solutions. Blood capillary space (1), endotheliocyte (2), cytotrabecula (3), cytopodia (4), basal membrane (5). x 17 000.

Submicroscopic examination on the 10th day of the experiment under conditions of correction of experimental pyelonephritis with application of ozonized solutions determines normalization of the ultrastructure of the kidney bodies. Numerous cytopodia emerge from the cytotrabeculae; they are not wide, elongated, clearly outlined. They contact with the basal membrane, small ficcures are seen between them (Fig. 5).

Electron microscopic examinations of the nephron canaliculi determined less marked structural changes and appearance of signs of epithelial cells reparation regeneration in their wall as compared to the group of animals without correction.

It should be noted that ultrastructural

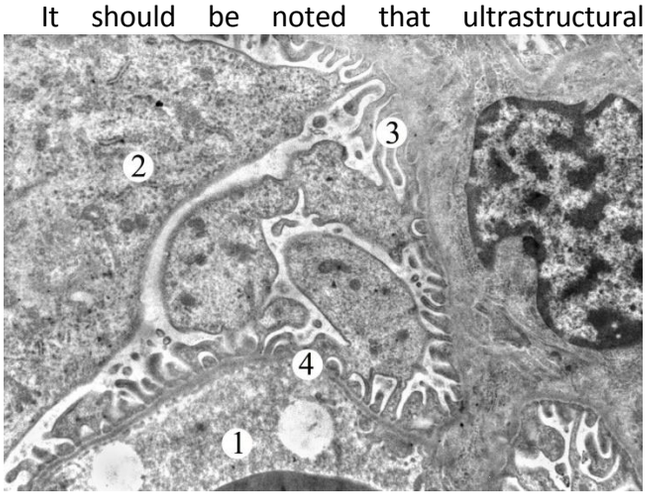

Fig. 5. Submicroscopic organization of the kidney body components in animals on the 10th day after experimental pyelonephritis and application of ozonized solutions. Blood capillary space (1), cytotrabecula (2), cytopodia (3), basal membrane (4). x 17 000.

examination of the material of this group of animals detected decrease of dystrophic changes in the kidney tissues, appearance of nephrocytes in the cytoplasm, a number of major mitochondria with preserved stellate electronic-dense granules of glycogen. The profiles of the uneven endoplasmic network and preserved canals with free lumen and narrow intercellular spaces are found. The villi of the brush frame are found on the apical surface of cells. In the areas of the interstitial fibrosis in the space between nephrocytes young fibroblasts with elongated dark electronic dense nuclei are seen.

The results obtained enable to conclude that ozone therapy effectively corrects changes of the kidney tissue caused by acute inflammatory process manifested by the absence of dystrophic and necrotic structures of the kidney parenchyma and tubular apparatus. On the basis of the above mentioned data a conclusion can be drawn concerning reasonability to use ozone therapy for the treatment of infectious-inflammatory kidney diseases. It is the most reasonable to be applied in postoperative therapeutic complex of such patients.

Therefore, the experiment conducted has made our knowledge concerning biomechanics and pathophysiological ways of development and formation of kidney damage deeper, which is taken into account while improving the existing and elaborating new methods of minor invasive surgery, in prognosis of the course and management of patients with urolithiasis after initiation of the suggested therapy using the series of distant shock-wave lithotripsy in association with ozone therapy.

Conclusions. The results obtained enable to conclude that ozone therapy effectively corrects changes of the kidney tissue caused by acute inflammatory process manifested by the absence of dystrophic and necrotic structures in the kidney parenchyma and tubular apparatus.

Prospects of further studies. further investigation of the ultrastructural rebuilding of the kidney tissue under conditions of pyelonephritis and ozone therapy will serve as a morphological basis to choose optimal methods of its prevention and treatment.

References.

1. *Bojagina OD, Izmajlova LV, Movchan JuA. Morfologicheskie osobennosti sosudov perikarda pri koronarnoj nedostatochnosti. In: Medicina tret'ogo tisjacholittja. Zb. tez mizhvuzivs'koï konf molodih vchenih ta studentiv; 2014 jan 14; Harkiv: Harkivs'kij nacion. med. universitet. 2014. p. 8.*
2. *Grigorova MV, Zinov'ev IE, Izmajlova LV. Morfologicheskie osobennosti nervov perikarda cheloveka. Morfologija organiv i tkanin u normi ta pid vplivom dejakih chinnikiv. Mater nauk-prakt konf stud ta molodih vchenih, prisv 90-richchju prof VV. Bobina; 2014 oct 21; Harkiv: Harkivs'kij nacion med universitet. 2014. p. 17-20.*
3. *Dzevul's'ka IV. Gemomikrocirkuljatorne ruslo perikarda ljudini v prenatal'nomu periodi ontogenezu [avtoref. dis...kand. med.nauk.] Kiïv: 2004. 24 p.*
4. *Dunaev OV. Dodatkovi dzherela kropostachannja sercja cherez veni subendokardial'nogo sudinnogo rusla pri rozladah koronarnogo krovotoku. Ukr morfol al'manah. 2011;(4):21-4.*
5. *Ljashhenko DN. Morfometricheskie harakteristiki vzaimootnoshenij serdca cheloveka s okruzhajushhimi organami na jetape rannego plodnogo perioda ontogeneza. VNMT. 2011;(2):128-30.*
6. *Shalikova LO. Osobennosti izuchenija fetal'noj topograficheskoj anatomii serdca, vnutriserdechnyh struktur i krupnyh sredostennyh sosudov cheloveka klassicheskimi morfologicheskimi metodami. Vestnik OGU. 2011;16(135):370-2.*
7. *Shvecov IM. Hirurgicheskaja anatomija i vozrastnye osobennosti sosudov perikarda cheloveka [avtoref. diss…dokt. med. nauk.] M: 1967. 28 p.*

CONTENT:

Deutscher Wissenschaftsherold
German Science Herald

Bibliographic information published by the Deutsche Nationalbibliothek
The Deutsche Nationalbibliothek lists this publication in the Deutsche Nationalbibliografie; detailed bibliographic data are available on the Internet athttp://dnb.dnb.de

№ 3/2017 – 23
Passed in press in August 2017