

ISSN 2509-4327 (print)
ISSN 2510-4780 (online)

Inter
GING



Deutscher Wissenschaftsherold German Science Herald

№ 6/2017

Die Zeitschrift „Deutscher Wissenschaftsherold“ ist eine Veröffentlichung mit dem Ziel ein breites Spektrum der Wissenschaft allgemeinverständlich darzustellen. Die Redaktionsleitung versteht sich als Vermittler zwischen Wissenschaftlern und Lesern. Durch die populärwissenschaftliche Bearbeitung wird es möglich unseren Lesern neue wissenschaftliche Leistungen am besten und vollständigsten zu vermitteln. Es werden Untersuchungen, Analysen, Vorlesungen, kurze Berichte und aktuelle Fragen der modernen Wissenschaft veröffentlicht.

Impressum

Deutscher Wissenschaftsherold – German Science Herald

Wissenschaftliche Zeitschrift

Herausgeber:

InterGING

Sonnenbrink 20

31789 Hameln, Germany

Inhaber: Marina Kisiliuk

Tel.: + 49 51519191533

Fax.: + 49 5151 919 2560

Email: info@dwherold.de

Internet: www.dwherold.de

Chefredakteur/Editor-in-chief:

Marina Kisiliuk

Korrektur:

O. Champela

Gestaltung:

N. Gavrilets

Auflage: № 6/2017 (Dezember) – 20

Redaktionsschluss Dezember, 2017

Erscheint alle 2 Monate

Editorial office: InterGING

Sonnenbrink 20

31789 Hameln, Germany

Tel.: + 49 51519191533

Fax.: + 49 5151 919 2560

Email: info@dwherold.de

Deutscher Wissenschaftsherold – German Science

Herald is an international, German/English language, peer-reviewed, twice a month published journal.

№ 6/2017

Passed in press in December 2017

Druck: WIRMachenDRUCK GmbH

Mühlbachstr. 7

71522 Backnang

Deutschland

Der Abdruck, auch auszugsweise, ist nur mit ausdrücklicher Genehmigung der InterGING gestattet. Die Meinung der Redaktion oder des Herausgebers kann mit der Meinung der Autoren nicht übereinstimmen. Verantwortung für die Inhalte übernehmen die Autoren des jeweiligen Artikels.

INDEXING: Google Scholar, WorldCat, Index Copernicus, InfoBase Index, Journal Index, Citefactor, International Scientific Indexing, JIFACTOR, Scientific Indexing Services, International Institute of Organized Research.



JIFACTOR



CiteFactor

Academic Scientific Journals



Scientific Indexing Services



INTERNATIONAL
Scientific Indexing



MIAR

<http://miar.ub.edu/issn/2509-4327>

© InterGING

© Deutscher Wissenschaftsherold – German Science Herald

Kasiyanchuk M.V.

Associate Professor Department of Prosthetic Dentistry, Higher State Educational Establishment of Ukraine "Bukovinian State Medical University", Private Specialized Medical Practice Chernivtsi, Ukraine

PREVENTION OF ATROPHY PROCESS OF THE COLLATERAL CREST BY MEANS OF CONJUNCTIVE APPLICATION OF DISCRETELY STABILIZED MESOSTRUCTURES ON IMPLANTS

Abstract. *The article deals with a topical issue of modern dental implantology: prevention of bone tissue loss after prosthetics using short and angular dental implants. The morphometric analysis in the problem area was carried out: X-ray control - analysis in dynamics during the post-implantation period in the longitudinal aspect. The effectiveness of the prosthetic method on implants, as a means of stabilizing atrophic processes of anatomical structures after teeth loss, was investigated. The influence of external factors on the stabilization process of bone structure remodeling during the post implantation period was studied.*

Key words: *dental implantation, angular implants, periosteum, bone atrophy of implant prosthesis, discreteness, stabilization.*

Introduction. Recently the method of dental implantation has occupied one of the leading places among dental surgery [1, 2]. New implant systems entering the market do not always enable clinicians to achieve a high esthetic result and effective restoration of functions of the human mastication apparatus. The methods and protocols assuming parallel existence of implants between themselves and adjacent teeth did not prevent completely manifestation of dystrophic processes in the periodontal tissues of the adjacent teeth or implants [3]. In Ukraine the offer of implant systems and qualification of dentists-orthopedists concerning implant prosthesis do not always satisfy European requirements [4]. The issues of implant prosthesis require a lot of time from a doctor and a patient. The tendencies of development of medical technologies promote introduction of own clinical methods in Ukraine considering European standards in dentistry [4].

A practical dentist has a task to restore (replace) lost anatomical structures of the collateral process so that complete the result of successful implantation [1-13]. A scientist has a task to find an alternative for classical methods of prosthesis which would prevent development of inflammatory-dystrophic processes in the periodontal tissues of the adjacent teeth or implants [1-3, 5-14].

We consider that one of the ways of their

prevention and preservation of biogenic (osteogenic) potential is introducing modern tendencies of prosthetic methods [1-7].

Numerous studies are indicative of the fact that occlusive load on implants (Fig. 1, 2) is considerably bigger than on natural teeth [5, 6]. And due to the absence of periodontal ligaments round the implant masticating pressure is transmitted directly onto the bone [5]. Implant producers suggest different ways to reduce masticating pressure. For example, IM2-implants have a built-in internal shock absorber (Chapman R, Kirsch A). This design assumes reduced action of only vertical forces transmitting through the implant not changing pathogenic tangential load. Periodical weakening of screw fixation (Fig. 1), abutments and even fractures of screws (Lang M, 2008) are found most often.

In certain cases the liner of prosthetic structures is determined, and the degree of risk increases with the use of angular implants (Zoeller J, 2013; Kasiyanchuk M, 2016). The use of implant supra-structures is a pathogenic factor for the periosteum of the area round the implant [12]. Adjustment of prosthetic structures resting upon numerous implants and abutments in spite of their way of manufacturing – cast or milled by means of CAD / CAM – methods do not pass the test on adjacent precision (White, 1993; Eisenmann 2004; Kasiyanchuk M, 2012, 2016). In

case of dental defects implants as supporting elements, fixators and stabilizers of prosthesis are used as the only measure to satisfy the patient's requirements concerning the quality of prosthesis; and internal bony implants and prosthetic structures with discrete time of fixation on them are preferred. The tendencies of development of medical technologies and scientific research concerning the use of short implants $L < 7\text{mm}$: (Nevins M, 2010; Ewers R, Neuqebauer J, 2016) promote introduction of own clinical methods considering European standards in dentistry [1-3, 5-14].

Available methods and materials do not involve possible clinical situations and all the possible factors of pathological effect in the periosteum area. Due to everything mentioned above on the basis of evidential medicine we have analyzed the efficacy of use of additional stabilization (splinting) in case of prosthetics on short

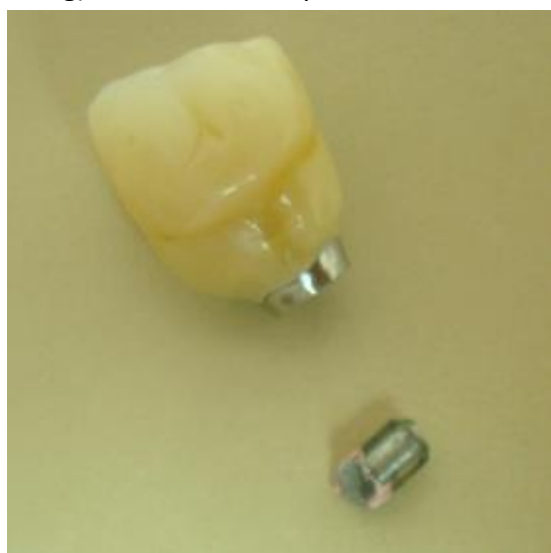

Fig.1. Clinical case: break of mesostructure on the implant.

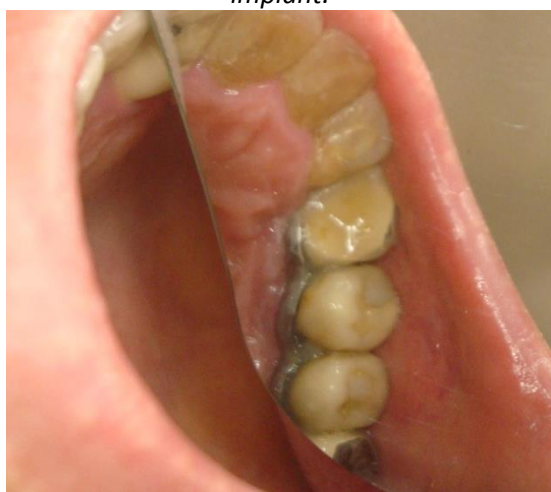

Fig.2. Clinical case: the use of stabilizing structure of multiple mesostructures on implants (own finding).

multiple implants to perform organ-saving prosthetics when other methods are not guaranteed at the dental clinic (dental implants) and do not assume the possibility of mesostructure service. We have used the methods of prosthetic rehabilitation of a patient based on biophysical regularities considering reparative possibilities of anatomical structures by the principle of discrete fixation and correction of the prosthetic structure [11, 14].

Objective: to determine the efficacy of use of mesostructure stabilization method on multiple implants to perform organ-saving prosthetics, assess correlation dependence of anatomical structures on the external and internal effecting factors.

Methods. The osseous tissue of the collateral process after teeth loss is formed without load occurring during mastication and it is a powerful stimulator of the osseous tissue formation. From the other side, the process of bone remodeling is affected by a number of factors analyzed in our study: age and sex of the patient, characteristics of hormonal state and metabolism, harmful habits, and the quality of food.

Selecting patients for implant prosthetics we have found certain signs (clinical symptoms) indicative of the fact that occlusive load after conjunctive use of implants changes on all the areas of the occlusive surfaces with a certain frequency of occurrence. Odontoglyphic examination in the longitudinal aspect determines the symptoms of hyperfunction of the masticating apparatus. Clinical cases were visualized by means of our own method [11, 15]. Availability of occlusive contacts and occlusive load was determined by Bausch method.

The clinical study included 40 patients after prosthetics on implants examined during 2007-2017 on the base of the private specialized dental clinic in the town of Chernivtsi and Department of Orthopedic Dentistry at the Higher State Educational Establishment of Ukraine "Bukovinian State Medical University". Men-women ratio was 1:2, an average age of patients was $43 \pm 4,7$. Descriptive and analytical design of the study keeping to the requirements of clinical investigations (informed consent) was used. Operative and diagnostic manipulations were performed by one operator under standard

conditions. The stages of laboratory examinations were carried out by one specialist during a short period of time in a specialized dental-technical laboratory. Applying titanium (alloy of the same name) we suppose to reduce the risk to corrosion due to the difference of potentials occurring between the implant and mesostructure (Beliayeva L,1988). In the comparative aspect we have produced a splinting (stabilizing) element (Fig. 3, 4) by means of milling or casting: adjacent precision was compared.

The patients were divided into three groups: the main one (experimental) included patients (10 individuals), the ratio of the supra-structure > infra-structure of the implant, who underwent prosthetics and stabilization of mesostructures according to our own methods, and there is no need to correct orthopedic structure on the implant. For the comparative analysis we have applied a comparable method of prosthetics on implant used in case of narrow location of the adjacent teeth and the implants D 2.8 mm. The mesostructures were lined with polymeric ceramic (composite ceramic, composite).

In this case the covering material performs the role of a shock absorber of masticating pressure.

The patients (10 individuals) from the control group included those who underwent prosthetics according to our own methods: the ratio of supra-structure > infra-structure of the implant who experienced complications (fracture, inadequate wearing of a prosthetic structure), cosmetic defect due to the process of remodeling of anatomical structures of the collateral process in the perigingival area, etc.

The control second group (10 patients) included individuals who underwent prosthetics

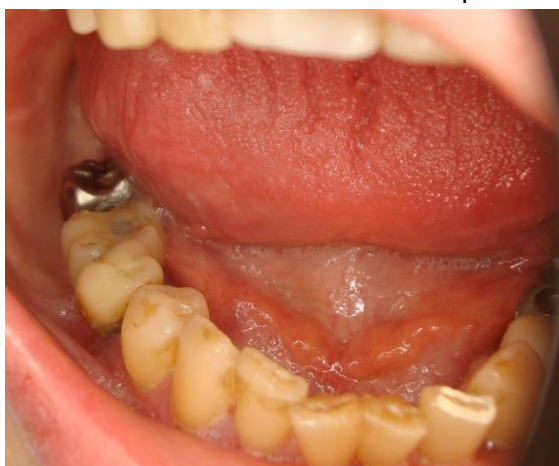

Fig.3. Clinical case: odontoglyphic peculiarities during post-implantation period, 8 years (own finding).

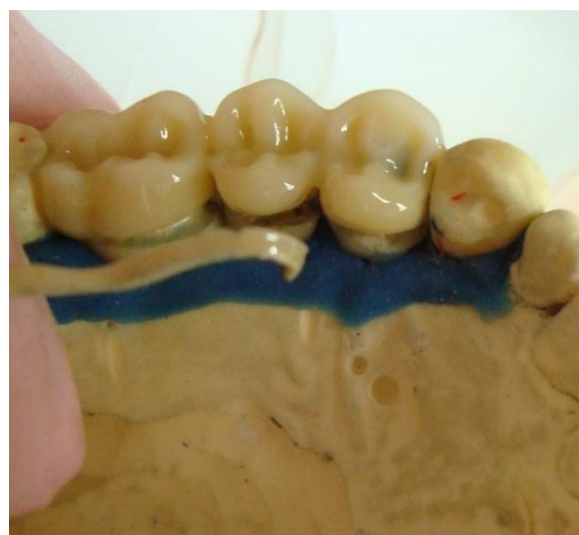

Fig. 4. Laboratory stage: adjustment of discrete stabilized prosthetic structure.

according to our own method with the ratio of supra-structure > infra-structure of the implant, although additional stabilization of the orthopedic structure on the implant was not used.

The third control group (10 patients) included those who underwent prosthetics according to the standard methods with the ratio of supra-structure > infra-structure of the implant with complications (fractures, inadequate wearing of the prosthetic structure), cosmetic defect due to the process of remodeling of the anatomical structures of the collateral process in the perigingival area, etc.

In all the cases we have determined the condition of the prosthetic structure (wearing, fracture, fixation). Latent inflammatory process of the soft tissues was determined by means of Shiller-Pisarev test (Pisarev Yu, 1956). To assess the efficacy of the prosthetic method we have examined objective parameters of patients from the main and control groups: the width of the collateral process, degree of vertical resorption of the osseous tissue during 10 years of patients' observation.

According to the data of producers all the covering materials had comparable adhesive properties to titanium frames in case of keeping to technological processes and are intended for covering titanium mesostructures on implants.

To assess the efficacy of the implantation method we have studied objective parameters of the osseous tissue atrophy in the patients of the experimental and control groups: degree of the vertical resorption of the osseous tissue during 12

months of patients' observation. Discrete fixation of the mesostructures enabled us to remove by means of laboratory methods fractures, cosmetic defect due to the process of remodeling of the anatomical structures of the collateral process in the perigingival area, etc. Additional augmentation was performed due to cosmetic causes while assessing vertical resorption of the osseous tissue in 2 patients. Analytical conclusion and statistical analysis were made by the obtained results.

Further observation of patients from the main and control groups during 10 years determined the following complaints: periodical unpleasant sensations in the gums, the need of special hygiene of the inter-implant spaces, etc., the necessity to correct odontoglyphic peculiarities. Clinical cases were visualized by means of our own method [11, 15].

To assess the efficacy of the prosthetics method we have studied objective parameters of the patients from the main and control groups: the width of the collateral process, degree of the vertical resorption of the osseous tissue. The comparative analysis enabled to draw a differential conclusion (stratification of clinical signs), to predict biological regularities of use of discrete orthopedic structures on the angular implants.

Certain parameters of the osseous tissue are always correlatively connected with peculiarities of the life style and harmful habits of patients. And in this aspect it is rather topical. Therefore, analysis of this dependence will enable to predict or avoid possible complications in case of conjunctive use of implant systems. In the dynamics of observations we have followed a number of correlative relations between the parameters of the osseous tissue condition of the collateral process and internal and external factors. We have examined the correlative dependence of the anatomical structures in case of conjunctive use of the implant and mesostructure depending on the sex and age of the patient. These factors included both the factors of a positive effect (intake of calcium containing drugs, sufficient dairy products every day), and the factors of a negative effect (smoking, regular alcohol intake, thyroid diseases and osteoporosis). Both clusters of factors are

connected between themselves by means of a logical link.

Results. Statistical analysis while making examination is the following: in the process of the conjunctive use of implants occlusive load changes on all the links of the occlusive surfaces in 70% of occurrence including those 82% of cases when occlusive load increased (Fig. 2) and requires correction.

In clinical examinations included 40 patients after implant prosthetics: examination of patients from the main group during 3 months did not find complaints. Changes of the gingiva and the problems with further prosthetics were determined with reliably less frequency (Fig. 5). In the cosmetic aspect the patients of the main group also gain benefit from it.

In patients of the main and experimental groups (* - difference probability $p < 0,05$) further examination during 12 months did not find any complaints ($p < 0,05$).

To assess the efficacy of the implant method objective parameters of the osseous tissue atrophy were studied in the patients from the

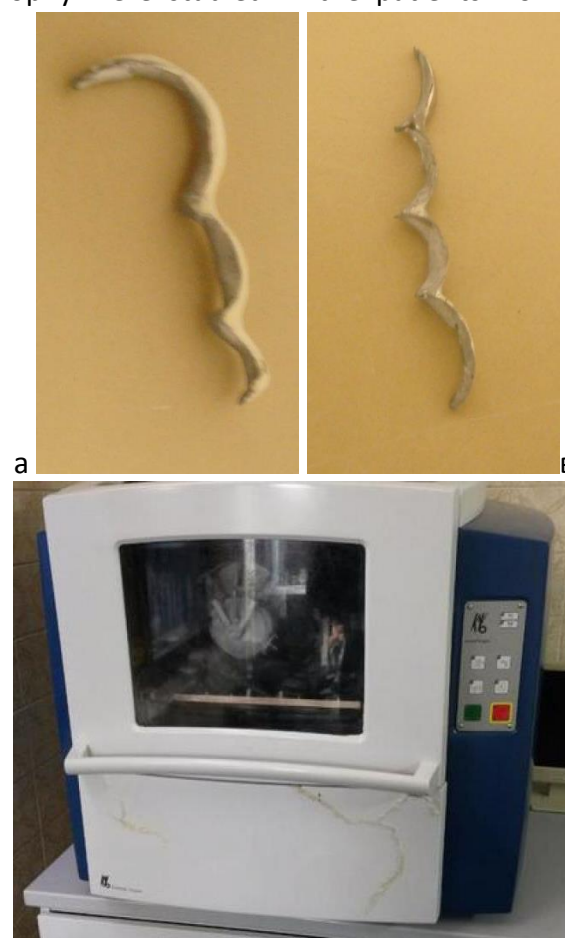


Fig. 5. Stabilizing (splitting) structures of mesostructures on implants produced by means of milling: in CAD / CAM.

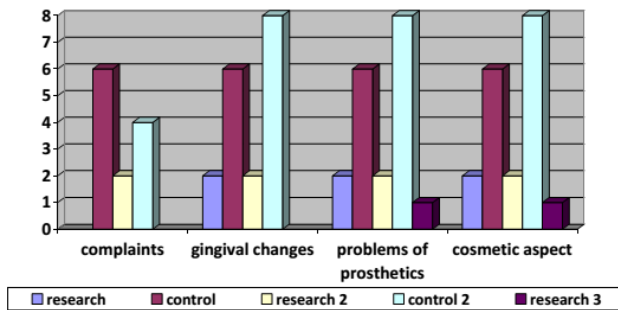


Fig. 6. Frequency of symptoms in the dynamics of post-operative period (3 months) in the patients of the main and experimental groups (difference probability $p < 0,05$).

main and control groups: degree of the vertical resorption of the osseous tissue during 12 months (Fig. 6.) of patients' observation. After assessment of vertical resorption of the osseous tissue, additional augmentation was performed in 2 patients of the main group due to cosmetic causes.

To assess the efficacy of the implant method objective parameters of 10 patients from the following groups were studied: the main one (with splinting) and the control group (without splinting) – the width of the collateral process, degree of the vertical resorption of the osseous tissue during 10 years of patients' observation. In the main and control groups the width of the collateral process after prosthetics differed reliably and was $7,4 \pm 2$ mm for both groups and $4,8 \pm 2$ mm for both groups ($p > 0,05$) now. Similar parameters are found in the assessment of vertical resorption of the osseous tissue.

Latent inflammatory process determined by means of Shiller-Pisarev test was found in 30% of cases in the control group and in 40% of cases of the main (experimental) group. Clinical manifestation of inflammation of the soft tissues was eliminated by the administration of laser therapy by means of the common methods.

We have found fractures of the covering in 20% of cases. Although, fractures of the covering were not diagnosed in case of inconsiderable width of the occlusive surface of the prosthetic structure concerning the diameter of the titanium frame (1/2), or the use of two supporting implants on one prosthetic structure in four patients of the control group (40%). In this group we did not find periodical weakening of the screw fixation of abutments which is the evidence of decreased

tangential dynamic load on the implants and peri-implant structures.

In the dynamics of observations we have followed the following regularities: the parameter of the bone proposition ($r = -0,44$, $p < 0,05$) and plane of the bone cut ($r = -0,39$, $p < 0,05$) had a negative correlation with thyroid diseases. We consider this effect is unlikely to be associated with the thyroid gland itself, but with the parathyroid glands regulating calcium metabolism, and which circulation can suffer due to pathology in this area.

Excessive body weight of the patient or obesity (body mass index (BMI) higher than 25 kg/m^2) had a negative correlation with the vertical size of the cellular bone in the dynamics ($r = -0,43$, $p < 0,05$). It also correlated positively with the bone type – the 3rd and the 4th type of the bone prevailed in those patients ($r = -0,46$, $p < 0,05$). Thus, this type of metabolic disorders correlated with more intensive course of atrophy. Correlative dependence of the collateral process tissue condition and the external and internal effect factors is graphically presented (Fig. 7, 8).

In case of necessity fractures of covering were corrected in laboratories due to discrete fixation (implanting) of the prosthetic structure making

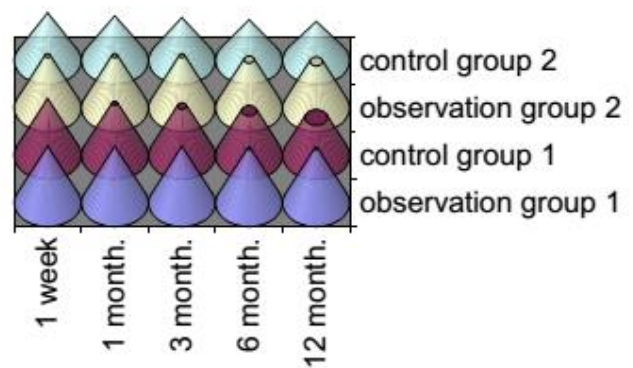


Fig. 7. Degree of vertical resorption (12 months).

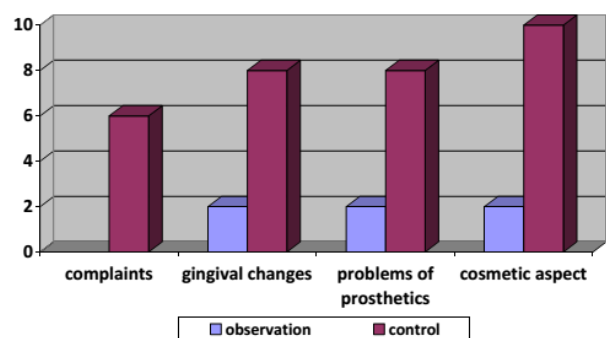


Fig. 8. Frequency of the symptoms in the dynamics in the longitudinal aspect (to 10 years) in patients of the main and experimental groups (difference probability $p < 0,05$).

the term of its service life longer. Unpredictable cementation loss was found in 2 cases of the main group. The problem was eliminated by means of a repeated fixation of the splinting structure.

Conclusion. After prosthetic treatment in the main group probable differences of the collateral process as compared to the control group were determined. After this prosthetic method was used, inconsiderable signs of atrophy of the collateral process in the periosteum area were detected after stabilizing remodeling as compared to the control group.

Conjunctive use of implants with corrected occlusive load of mesostructures can serve as a stabilizer of remodeling the periosteum of the peri-implant zone after teeth loss in the past. The suggested method improves the process of prosthetic rehabilitation, maintenance of favourable conditions of atrophic structures of the collateral process for the realization of the own human osteogenic potential in case of prosthesis of the lost teeth.

Prospects of further studies. Investigation and further development of prosthetic methods based on biophysical regularities considering reparative possibilities of the anatomical structures will enable to create a unique chance to preserve own human tissues, and favourable conditions for the service of dental implants.

References:

1. *Abstract conference materials: conference materials. International Osteology Symposium in Monaco 2016. Osteology Foundation, Switzerland. 2016;36 P.*
2. *Abstract conference materials: conference materials. International Osteology Symposium in Verona 2016. Osteology Foundation, Italy. 2016;82.*
3. *Experten Symposium BDIZ EDI in Cologne. Application of angular implants. EDI Jornal. 2016;(1):12-6.*
4. *Voronenko YuV, Volosovets OP, Veigl P, Pavlenko OV. Materiali mizhnarodnoyi konferentsiyi. Vprovadzhennya Evropeyskikh standartiv v Ukrayini. Kiyiv, 2015.*
5. *Richter L. In vivo vertical forces on implants. International Journal of Oral & Maxillofacial. 1995;10:326-34.*
6. *Weinberg L. The Biomechanics of Force Distribution in Implant-Supported Protheses. Int j oral maxillofac implants.1993;8:19-31.*
7. *Kasiyanchuk MV. Protetika na implantatah yak zasib zberezhennya biogennogo (osteogennogo) potentsialu. Novini stomatologiyi. 2017;3:19-24.*
8. *Kasiyanchuk MV, Prognozuvannya osteogennogo potentsialu lyudini v aspekti sudovo-medichnoyi ekspertizi. Propozitsiya vlasnoyi metodiki doslidzhennya. Materiali mizhnarodnoyi konferentsiyi. Aktualni pitannya sudovo-medichnoyi ekspertizi. Chernivtsi, 2013:34-5.*
9. *Richter L, In vivo vertical forces on implants. International Journal of Oral & Maxillofacial. 1995;10:326-34.*
10. *Weinberg L, The Biomechanics of Force Distribution in Implant-Supported Protheses. Int j oral maxillofac implants. 1993;8:19-31.*
11. *Kasiyanchuk MV. Zastosuvannya printsipu diskretnosti pri protezuvanni na implantati. Materiali naukovopraktichnoyi konferentsiyi. Innovatsiyini tehnologiyi v suchasniy stomatologiyi. Ivano-Frankivsk. 2017; P. 35-6.*
12. *Engquist B, Astrand P, Dahlgren S. Marginal bone reaction to oral implants: a prospective comparative study of Astra Tech and Branemark System implants. Clin. Oral implants. Res. 2002.*
13. *Угрин ММ. Досвід використання імплантів вітчизняного виробництва при заміщенні дефектів зубних рядів. Актуальні проблеми ортопедичної стоматології. Львів. 1996:21.*
14. *Ozhogan ZR. Kliniko-eksperimentalne obgruntuvannya ortopedichnogo metodu likuvannya znimnimi mostovidnimi protezami z diskretnim chasom fiksatsiyi. Ivano-Frankivsk. 2003:376 P.*
15. *Kasiyanchuk MV, Kuhtaruk DR, Kaslyanchuk YuM. Optimizatsiya klinichnih vnutrishno rotovih doslidzhen. Materiali 97 pidsumkovoyi naukovoyi konferentsiyi profesorsko-vikladatskogo personalu vischogo derzhavnogo navchalnogo zakladu Ukrayini „BDMU”; Chernivtsi: 2016..*