

Kholodkova Y.L.,
Tsiurupa A.V.

Department of Human Anatomy of Odessa National Medical University, Odessa, Ukraine, sonshine22@ukr.net

COMPARISON OF PLATELET-RICH PLASMA AND NONSTEROIDAL ANTIINFLAMMATORY DRUGS EFFECTIVENESS FOR CORRECTION OF DEGENERATIVE DYSTROPHIC CHANGES IN THE VERTEBRA AND INTERVERTEBRAL DISCS

Abstract. *The paper gives a comparative analysis of the efficiency of platelet-rich plasma and diclofenac sodium, as frequently used non-steroidal anti-inflammatory drug for correcting degenerative dystrophic lesions of the spine. The introduction of diclofenac sodium in short courses did not produce any effect. It has been proved that the introduction of platelet-rich plasma inhibits the development of degenerative processes and promotes the spinal tissue regeneration.*

Key words. *degenerative dystrophic changes of the spine; non-steroidal anti-inflammatory drugs; platelet-rich plasma; correction; intervertebral disc.*

Introduction. Degenerative-dystrophic changes of the spine (DDCS) remain one of the most urgent medical problems today. According to WHO the incidence of dorsopathies in the developed countries is pandemic [1], resulting in temporary or permanent disability. Every year around a million patients in Ukraine seek medical attention in connection with DDCS of varying severity and over 16 thousand of them become disabled [2].

DDCS treatment is always comprehensive and includes measures aimed at reducing the load on the spine, physiotherapy, reflex therapy, manual and medication therapies. [3] As to the medication, non-steroidal anti-inflammatory drugs (NSAIDs) are often used in acute periods for the relief of pain attacks and relieving tissue edema. However, among the classic arsenal there are no effective drugs that improve the supply of nutrients to damaged tissue and stimulate tissue regeneration and revascularization.

In recent years, more and more attention of clinicians have been paid to using the platelet-rich plasma (PRP). This method is based on the use of a number of growth factors contained in platelets and involved in neoangiogenesis processes, proliferation and tissue regeneration [4].

Objective: to study of the effectiveness of using the platelet-rich plasma and its

comparison with NSAIDs (diclofenac sodium) for DDCS correction in experimental animals.

Materials and methods. The experiment included 60 mature Wistar, divided into 3 groups: group I - the animals with DDCS; group II - animals with DDCS and a correction with NSAIDs; group III - animals with DDCS and a correction with PRP. A separate group of animals served as an untreated control.

Simulating DDCS pathology in experimental animals was carried out by forming a permanent asymmetric static compression-distension of the caudal vertebral column [5] according to general ethical principles of animal experiments (I National Congress on Bioethics, of 20.09.2001, Kyiv), the Law of Ukraine «Protection of animals against cruel treating» № 27, Art. 230 of 2006, as amended in accordance with the Law N 1759-VI (1759-17) of 15.12.2009, VVR, 2010, N 9, Article 76., as well as the Code of Ethics of the scientists of Ukraine (Ukrainian National Academy of Sciences, 2009).

The animals were taken out of the experiment by euthanasia (inhalation overdose of ether). The results were evaluated 60 days after the beginning of the pathology simulation.

The platelet-rich plasma was produced by its separation from the whole blood on the unit SmartPrep (manufacturer Harvester Corp, USA), the state registration certificate №10179 / 2011 in accordance with the Decree of the Ministry of

Health of Ukraine of 08 February 20011, №69. As NSAIDs diclofenac sodium was used (R.P. number UA / 10237/01/01) at the rate of 1 mg / kg for 5 days. NSAIDs and PRP were injected into the base of the tail.

We used the material of the vertebrae and intervertebral discs (IVD) for pathological studies according to standard procedures [6].

Results and discussions. In histological specimens of group I we observed a significant asymmetry of IVD structures and expressed pathological changes in them. On the side of the compression the fibrous ring is significantly thinner compared to that in the intact animals. A significant shift of the vertebral pulp towards distension is observed. Maximum signs of degenerative and dystrophic lesions of the fibrous ring were marked on the compression side. The collagen plates of the fibrous ring looked stratified and flattened, with areas of disorganization and a variety of polymorphic slots. In these areas we observed multiple fiber necrosis foci which sometimes reached the epiphysis. Pathological changes of the vertebral pulp were presented with a decrease in its volume; on the side of its compression we marked impressions of the collagen fibers in the cavity of the vertebral pulp; in some places there was a pronounced vacuolization of notochordial cells and necrosis foci. The height of the epiphyses on the compression side was slightly higher, there were also chondronecrosis foci.

The animals of group II after a correction with NSAIDs also had degenerative-dystrophic changes in the tissues of the vertebrae and the IVD. The degree of asymmetry of the structures was unchanged in comparison with the animals in group I. There was a little lesser degree of collagen fibers stratification and a little larger thickness of the fibrous ring on the compression side, respectively. The number of necrosis foci remained unchanged (Fig 1).

After a correction with the PRP in animals of group III there was a significant decrease in the number of fibronecrosis foci, large thickness of the fibrous ring on the side of the compression, smaller degree of collagen fibers stratification. There was a slight reduction in tissue asymmetry between compression and distension sides. A

slight decrease in the number of foci of notochordial cells necrosis and a change in the height of the epiphysis of the vertebral bodies were also observed. The asymmetry of the IVD vertebral pulp location remained (Figure 2).

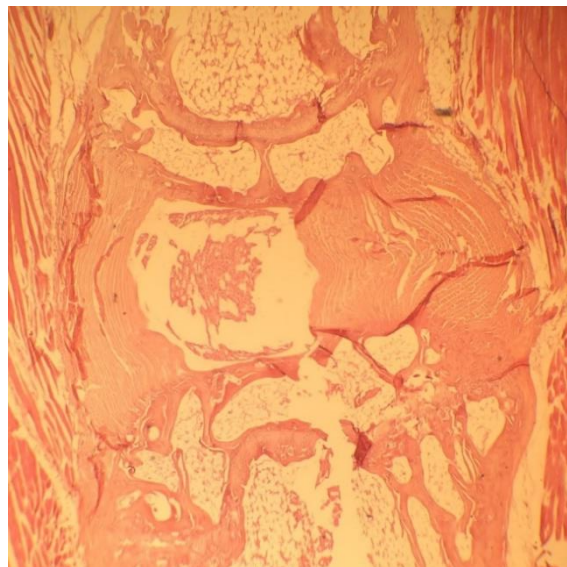


Fig. 1. An area of IVD of a rat from group II stained with hematoxylin and eosin. Magn. x 40.

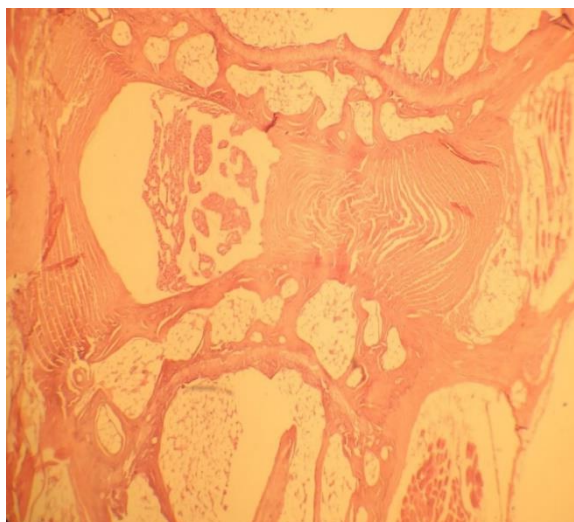


Fig. 2. An area of IVD of a rat from group III stained with hematoxylin and eosin. Magn. x 40.

The findings suggest that NSAIDs, without possessing a regenerative potential are not able to adequately counteract the pathological factors and do not produce significant anti-inflammatory effect in the DDCS. Using the PRP, which contains a great number of growth factors [7], stimulates the processes of regeneration and neoangiogenesis, reduces the severity of DDCS. A comparative evaluation of the effectiveness of NSAIDs and PRP correction

showed that the use of PRP reduces the severity of DDCS effectively, stimulating regenerative processes, reduces the degree of ischemic damage and promotes the recovery of the tissue structure.

Conclusions. Using the PRP for DDCS correction has a strong positive effect, while the use of NSAIDs has no significant impact on the course of the pathological process.

Prospects for further research. We are going to carry out more research on the PRP positive effect duration, to elaborate introducing schemes of PRP in the DDCS zone, to study more in details of the formation of vascular network in the DDCS zone. We need to find correction techniques for the location of the IVD vertebral pulp.

References:

1. Bogduk N / *Medical management of acute and chronic low back pain.* / Bogduk N, Mc Guirk B // Amsterdam: Elsevier, 2002.
2. Аль-Замиль М.Х. Анализ корреляции морфологических и анамнестических данных при остеохондрозе пояснично-крестцового отдела позвоночника / М.Х. Аль-Замиль, А. В. Мосейчук // *Клиническая неврология.* – 2008. – № 4. – С. 7-9.
3. Восстановительное лечение остеохондроза позвоночника / И.Л. Пшеетаковский, И.П. Шмакова. – Одесса: Астропринт, 2009. – 112 с. – Библиогр.: с. 111 – рус.
4. Robert E. Mars / *Platelet-Rich Plasma (PRP): What is PRP and What is not PRP?* / Robert E. Mars // *Implant dentistry.* – 2001. Vol. 10. – P. 225-228.
5. Пат. № 106085 / Спосіб моделювання дегенеративно-дистрофічного ураження хвостового відділу хребта у щурів / Заявл. 18.11.15/ Опуб 11. 04. 16/ Бюл. № 7 / О.Л. Холодкова., О.В. Цюрупа, І.Ю.Бадьїн.
6. Методики морфологічних досліджень : монографія / М54 Багрій М.М., Діброва В.А., Попадинець О.Г., Грищук М.І. ; за ред.. М. М. Багрія, В.А. Діборови. – Вінниця : Нова книга, 2016. – 328 с. ISBN 978-978-966-382-594-6
7. Platelet content and growth factor release in platelet-rich plasma: a comparison of four different systems / G. C. Leitner, R. Gruber, J. Neumüller [et al.] // *Vox Sang.* – 2006. – Vol. 91. – P. 135 - 139.