ISSN 2509-4327 (print)
ISSN 2510-4780 (online)

Deutscher Wissenschaftsherold
German Science Herald

№ 2/2017

Die Zeitschrift „Deutscher Wissenschaftsherold" ist eine Veröffentlichung mit dem Ziel ein breites Spektrum der Wissenschaft allgemeinverständlich darzustellen. Die Redaktionsleitung versteht sich als Vermittler zwischen Wissenschaftlern und Lesern. Durch die populärwissenschaftliche Bearbeitung wird es möglich unseren Lesern neue wissenschaftliche Leistungen am besten und vollständigsten zu vermitteln. Es werden Untersuchungen, Analysen, Vorlesungen, kurze Berichte und aktuelle Fragen der modernen Wissenschaft veröffentlicht.

Impressum
Deutscher Wissenschaftsherold – German Science Herald
Wissenschaftliche Zeitschrift
Herausgeber:
InterGING
Sonnenbrink 20
31789 Hameln, Germany
Inhaber: Marina Kisiliuk
Tel.: + 49 51519191533
Fax.:+ 49 5151 919 2560
Email: info@dwherold.de
Internet:www.dwherold.de
Chefredakeur/Editor-in-chief:
Marina Kisiliuk
Korrektur:
O. Champela
Gestaltung:
N. Gavrilets

Auflage: № 2/2017 (Juli) – 25
Redaktionsschluss Juli, 2017
Erscheint vierteljährlich
Editorial office: InterGING
Sonnenbrink 20
31789 Hameln, Germany
Tel.: + 49 51519191533
Fax.:+ 49 5151 919 2560
Email: info@dwherold.de
Deutscher Wissenschaftsherold - German Science Herald is an international, German/English language, peer-reviewed, quarterly published journal.
№ 2/2017
Passed in press in July 2017
Druck: WIRmachenDRUCK GmbH
Mühlbachstr. 7
71522 Backnang
Deutschland

INDEXING: Google Scolar, WorldCat, InfoBase Index, Journal Index, Citefactor, International Scientific Indexing, JIFACTOR, Scientific Indexing Services, International Institute of Organized Research.

http://miar.ub.edu/issn/2509-4327

REDAKTIONSKOLLEGIUM / INTERNATIONAL EDITORIAL BOARD:

Lists of references are given according to the Vancouver style

DDC-UDC 611.11:611.941]-053.15 DOI:10.19221/201723

Khmara T.V.,
Doctor of Medical Sciences, Professor, N.H. Turkevych Department of human anatomy of the Higher State Educational Institution of Ukraine "Bukovinian State Medical University", Chernivtsi, Ukraine, khmara_tv@mail.ru
Okrim I.I.,
Biriuk I.G.,
Candidate of Medical Sciences, Associated Professor, Department of Disaster Medicine and Military Medicine, Higher State Educational Institution of Ukraine "Bukovinian State Medical University", Chernivtsi, Ukraine,
Komar T.V.,
Khmara A.B.

TOPOGRAPHIC-ANATOMICAL PECULIARITIES OF BLOOD SUPPLY AND INNERVATION OF THE PERICARDIUM IN HUMAN FETUSES

Abstract. *Macroscopic examination of the variants of blood supply and innervation of the pericardial um was carried out on 17 specimens of 6-7-month human fetuses. Certain topographic-anatomical peculiarities of the pericardial-diaphragmatic arteries were found. Asymmetric location of the vascular-nervous bundle of the pericardium was described. The right pericardial-diaphragmatic artery and the right diaphragmatic nerve have a winding passage and greater number of branching. It should be noted that diaphragmatic nerves form nerve plexuses innervating anterior-lateral parts of the pericardium and participate in the formation of paravascular plexuses of the internal thoracic artery.*
Key words: *pericardium, pericardial-diaphragmatic vessels, internal thoracic vessels, diaphragmatic nerve, fetus.*

Introduction. Due to an increased rate of cardio-vascular diseases and congenital heart defects investigation of the problems of formation and development of blood supply to the heart and pericardium during the prenatal period of human ontogenesis has become rather topical. Modern scientific literature contains information concerning additional sources of blood supply in case of disorders of the coronary circulation paying attention to the topography of the pericardial vessels [1, 4]. Vascular network of the pericardium connects the myocardial vessels with the vessels of the organs of the anterior and posterior mediastinum, diaphragm, bronchial and esophageal vessels [3, 5]. Rapid development of perinatal medicine and neonatology requires a detailed study of interrelations of the heart vessels with surrounding structures to perform more accurate surgery [5, 6]. Investigation of innervation of the mediastinal organs through the adjacent location of vessels and nerves deserves no less attention [2]. Although, the sources of blood supply and innervation of certain parts of the pericardium during the fetal development of human ontogenesis are not examined sufficiently.

Objective: to find the sources of blood supply and innervation of the pericardial parts in 6-7-month fetuses.

Materials and methods. Macroscopic examination of typical and variant anatomy of vessels and nerves of the pericardium has been carried out on 17 specimens of human fetuses 186,0-270,0 mm of the parietal-coccygeal length (PCL) by means of the methods of anatomical dissection and vascular injection.

Results of the study and their discussion. The pericardium is known to have the anterior – sternal-costal, two lateral – the right and left mediastinal, and inferior – diaphragmatic parts (walls). According to the data presented by I.M. Shvetsov [7] while lining horizontally on the level of the inferior border of the lung root, the anterior and anterior-lateral parts of the pericardium are divided into two portions: upper and lower. Due to this fact 6 segments are differentiated in the sternal-costal part of the pericardium: 2 anterior and 4 anterior-lateral. Examination of fetuses found pericardial-diaphragmatic vessels accompanied by diaphragmatic nerve passing both on the right and on the left between the pericardium and mediastinal part of the deciduous pleura. Location of the right and left vascular-nervous bundles of the pericardium is asymmetrical. The right vascular-nervous bundle

of the pericardium is shorter. Thoracic portion of the diaphragmatic nerve is located asymmetrically on the right and on the left. The right diaphragmatic nerve passes to the pericardium joining the wall of the upper hollow vein (vena cava), and on the very pericardium the nerve is covered with the deciduous pleura. In the area of the pericardium the right diaphragmatic nerve is located anteriorly, or sometimes (5 cases) directly near the root of the right lung. Inferior thoracic part of the right diaphragmatic nerve passes along the inferior hollow vein (vena cava), along its lateral surface. The left diaphragmatic nerve passes to the pericardium along the lateral surface of the hemiazygos vein, and then it is located anteriorly from the root of the left lung. At the same time, pericardial portion of the left diaphragmatic nerve is longer than that of the right one (Fig. 1).

Since the right and left diaphragmatic nerves are topographically located anteriorly from the root of an appropriate lung, vagus nerves pass posteriorly from the lung root (Fig. 2). The right and left diaphragmatic nerves participate in the formation of nerve plexuses of the pericardium, and together with branches of vagus nerves and sympathetic trunks form paravascular plexuses of the internal thoracic artery. Diaphragmatic nerves innervate anterior-lateral portions of the pericardium.



Fig. 1. Organs and structures of the thoracic cavity of the fetus with 230,0 mm PCL. Macrospecimen. Anterior-left view. Magnification 2,5^{x}: 1 – heart covered with pericardium; 2 – left pericardial-diaphragmatic vessels; 3 – left diaphragmatic nerve; 4 – branches of the muscular-diaphragmatic artery; 5 – retrosternal gland

The pericardial-diaphragmatic artery passes from the internal thoracic artery on the level of I rib, and together with the diaphragmatic nerve runs to the caudal direction. In the anterior part of the mediastinum 3 branches pass from the pericardial-diaphragmatic artery, mainly from the left one: superior, anterior and inferior supplying lateral surfaces of the pericardium, mediastinal part of the deciduous pleura and diaphragm. At the same time, the areas of blood supply of the left pericardial-diaphragmatic artery are bigger than those of the similar right artery. The right pericardial-diaphragmatic artery and the right diaphragmatic nerve have winding passages and a greater number of branching. The number of branches of the right pericardial-diaphragmatic artery is usually 4-6 (Fig. 3).

The superior part of the anterior portion of the pericardium is supplied with blood by means of the branches of the retrosternal gland, and venous outflow is carried along the retrosternal

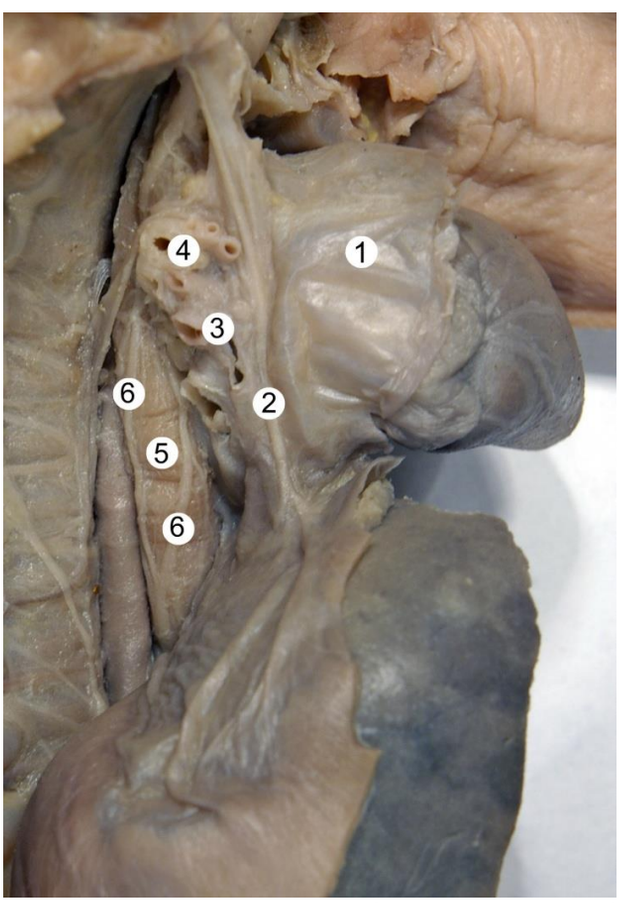

Fig. 2. Organs and structures of the mediastinum of the fetus with 215,0 mm of PCL. Macrospecimen. Right view. Magnification 3,2^{x}: 1 – right atrium covered with pericardium; 2 – pericardial-diaphragmatic vessels and diaphragmatic nerve; 3 – right pulmonary veins; 4 – root of the right lung; 5 – esophagus; 6 – branches of the right vagus nerve

vein into the system of the internal thoracic vein. The inferior part of the anterior portion of the pericardium is supplied with blood by means of the mediastinal branches of the internal thoracic artery and anterior branch of the pericardial-diaphragmatic artery. The outflow of venous blood is carried along the similar vessels into the internal thoracic vein.

The superior part of the anterior-lateral portion of the pericardium in the right and left is supplied with blood by means of the superior branch of an appropriate pericardial-diaphragmatic artery. The outflow of the venous blood is carried through the similar vein into the brachial-cephalic vein, sometimes – into the internal thoracic vein. It should be noted that two left internal thoracic veins (middle and lateral) were found on 9 specimens out from 17 examined fetuses, and two right ones – only in 6 fetuses; and the internal thoracic artery is located between the same veins. Fusion of the left middle and lateral internal thoracic veins occurs, as a rule, in the 2-3 intercostal space (7 cases out of 9), and the right similar veins – in 3-4 intercostal space (4 cases out of 6). One internal thoracic vein along the whole length of the similar artery was found in the left in 8 fetuses, and in the right – in 11 examined fetuses. Arcuate anastomosis between the right and left middle internal thoracic veins was found anteriorly from the inferior third of the sternal body in 4 cases.

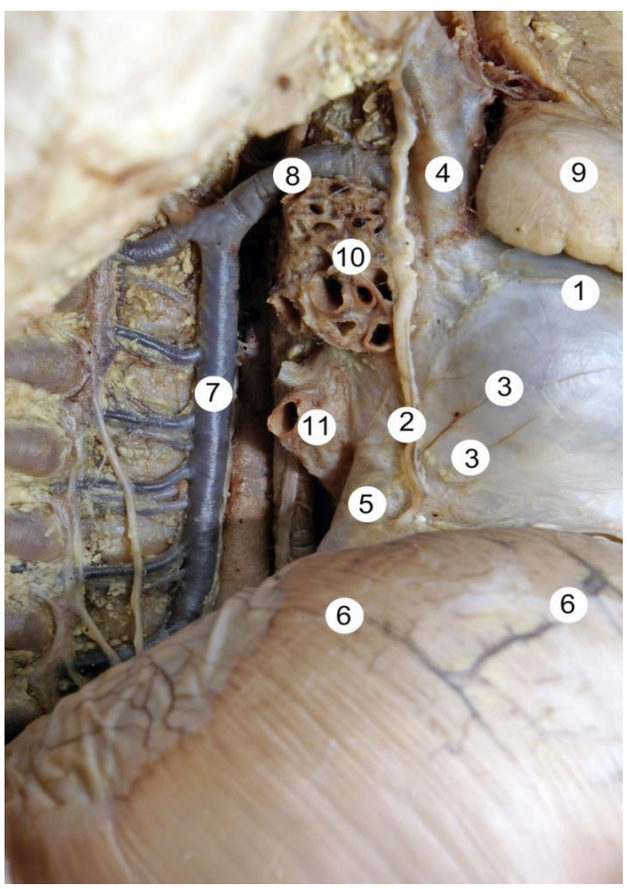

Fig. 3. Organs and vessels of the superior and middle mediastinum of the fetus with 270,0 mm of PCL. Macrospecimen. Right view. Magnification 3,7^{x}: 1 – right atrium covered with the pericardium; 2 – pericardial-diaphragmatic vessels and diaphragmatic nerve; 3 – branches of the pericardial-diaphragmatic artery; 4 – superior vena cava; 5 – inferior vena cava; 6 – muscular-diaphragmatic vessels; 7 – azygos vein; 8 – arch of the azygos vein; 9 – right lobe of the retrosternal gland; 10 – root of the right lung; 11 – right pulmonary veins

The inferior part of the anterior-lateral portion of the pericardium is supplied with blood by means of the inferior branch of the pericardial-diaphragmatic artery and bronchial branches. Venous outflow is carried into the inferior diaphragmatic vein. The diaphragmatic part of the pericardium is supplied with blood by means of the branches of the superior and inferior diaphragmatic arteries, and venous outflow – into the similar veins. The posterior wall of the pericardium is supplied with blood by means of the bronchial branches, and venous outflow is carried into the azygos and left brachial-cephalic veins. The posterior part of the mediastinum is supplied with blood by means of the bronchial and esophageal branches. In fetuses due to a weak development of the cellular tissue of the mediastinum the posterior wall adjoins the esophagus, trachea, bronchi, aorta, vagus nerves and pleura.

Conclusions: 1. The major vessels ensuring blood supply of the anterior-lateral parts of the pericardium are pericardial-diaphragmatic arteries. The latter together with diaphragmatic nerves form vascular-nervous bundle of the pericardium. Location of the right and left vascular-nervous bundles of the pericardium is asymmetrical, and the right vascular-nervous bundle of the pericardium is shorter.

2. The areas of the blood supply of the left pericardial-diaphragmatic artery are bigger than those of the similar right artery.

3. The right pericardial-diaphragmatic artery and right diaphragmatic nerve have a winding passage and greater number of branching.

4. the right and left diaphragmatic nerves

participate in the formation of nervous plexuses of the pericardium, and together with branches of the vagus nerves and sympathetic trunks form the paravascular plexuses of the internal thoracic artery. Diaphragmatic nerves innervate anterior-lateral portions of the pericardium.

Prospects of further studies. The investigation is indicative of the necessity to conduct further study of the variant anatomy of blood supply and innervation of the pericardium in human fetuses of various age groups.

References:

1. *Boyagina OD, Izmaylova LV, Movchan YuA. Morfologicheskie osobennosti sosudov perikarda pri koronarnoy nedostatochnosti. In: Meditsina tretogo tisyacholittya. Zb. tez mizhvuzivskoyi konf. molodih vchenih ta studentiv; 2014 sichnya 14; HarkIv. HarkIv: Harkivskiy natsion. med. universitet; 2014. p. 8.*
2. *Grigorova MV, Zinovev IE, Izmaylova LV. Morfologicheskie osobennosti nervov perikarda cheloveka. In: Morfologiya organiv i tkanin u normi ta pid vplivom deyakih chinnikiv. mater. nauk.-prakt. konf. stud. ta molodih vchenih, prisv. 90-richchyu prof. V.V. Bobina; 2014 zhovtnya 21; Harkiv. Harkiv: Harkivskiy natsion. med. Universitet; 2014. p. 17-20.*
3. *Dzevulska IV. Gemomkrotsirkulyatorne ruslo perikarda lyudini v prenatalnomu periodi ontogenezu [avtoreferat]. Kyiv; 2004. 24 p.*
4. *Dunayev OV. Dodatkovi dzherela kropostachannya sertsya cherez veni subendokardialnogo sudinnogo rusla pri rozladah koronarnogo krovotoku. Ukr morfol almanah. 2011; (4):21-4.*
5. *Lyaschenko DN. Morfometricheskie harakteristiki vzaimootnosheniy serdtsa cheloveka s okruzhayuschimi organami na etape rannego plodnogo perioda ontogeneza. VNMT. 2011;(2):128-130.*
6. *Shalikova LO. Osobennosti izucheniya fetalnoy topograficheskoy anatomii serdtsa, vnutriserdechnyih struktur i krupnyih sredostennyih sosudov cheloveka klassicheskimi morfologicheskimi metodami. Vestnik OGU. 2011; 135(16):370-2.*
7. *Shvetsov IM. Hirurgicheskaya anatomiya i vozrastnyie osobennosti sosudov perikarda cheloveka [avtoreferat]. M; 1967. 28 p.*

CONTENT:

Deutscher Wissenschaftsherold
German Science Herald

Bibliographic information published by the Deutsche Nationalbibliothek
The Deutsche Nationalbibliothek lists this publication in the Deutsche Nationalbibliografie; detailed bibliographic data are available on the Internet athttp://dnb.dnb.de

№ 2/2017 – 26
Passed in press in July 2017