

Zubko L.Yu.,
Masna Z.Z.

Danylo Halytskyi Lviv National Medical University, Lviv, Ukraine

MORPHOLOGICAL PECULIARITIES OF THE GALLBLADDER STRUCTURE AND ITS FUNCTIONAL CHANGES IN HEALTHY INDIVIDUALS OF DIFFERENT SEXES ACCORDING TO THE FINDINGS OF ULTRASOUND EXAMINATION

Abstract. Pathology of the hepatic-duodenal area (HDA) constitutes 25% of all the patients with affliction of the abdominal organs. Making a correct diagnosis in patients with HAD lesions is a complicated issue due to the lack of early pathognomonic symptoms (to the moment jaundice appears), similar clinical manifestation at the stage of jaundice development, absence of specific markers, complicating pre-surgical differential diagnostics of surgical group of diseases. Detection of individual lifetime anatomical structure of a healthy man and finding pathology at early stages of diseases in order to prevent their development have become of a topical value for diagnostic direction of practical medicine. The possibility to apply mini-invasive radiation methods of examination promotes the solution of the task. Objective of our study was to determine the frequency of occurring morphological peculiarities of the gallbladder structure and its functional changes that can be risk factors promoting development of bile expelling structure pathology in healthy adult individuals of different sexes according to the findings of ultrasound examination of the HDA organs. To determine the sickness rate of gallbladder and bile ducts diseases 136 adult people were examined by means of the ultrasound apparatus «Radmir Ultima RU-928» including 60 (44,1%) men and 76 (55,9%) women. The investigation was conducted by means of a convective sensor with the frequency band from 1 to 5 mHz ($\pm 0,5$ mHz) R60 mm. The results of the investigations conducted were indicative of the fact that screening ultrasound diagnostic examinations enable to find both morphological peculiarities of the gallbladder structure and its functional disorders, cholestasis in adult patients without complaints and clinical manifestation of HDA pathology in particular. Among the examined 77 healthy adult individuals including 37 men and 40 women gallbladder flexion was found in 18,2% from the general number of those being examined (21,6% of men and 15% of women). Examination detected asymptomatic cholestasis in 16 people which is 20,8% from general number of those healthy examined ones including 18,9% of men and 22,5% of women. Detection of morphological peculiarities of the gallbladder structure and early diagnostics of cholestasis in individuals without complaints and clinical manifestation of HAD pathology will enable to increase the efficacy of preventive measures directed to maintenance of functional ability of the examined structures.

Key words: gallbladder, morphological peculiarities, functional changes, adult individuals, hepatic-duodenal area.

Introduction. Pathological processes localized in the structures of the hepatic-duodenal area (HDA) are extremely diverse and very often combined. The results of numerous scientific studies indicate that HAD pathology takes the second place by the frequency of lesions after acute appendicitis, or it constitutes one fourth of the general number patients with affliction of the abdominal organs [3, 6].

In spite of rather high technical level of up-to-date diagnostic methods making the correct

diagnosis in patients with HAD pathology remains a complicated issue [4, 8]. The lack of early pathognomonic symptoms (to the moment jaundice appears), similar clinical manifestation at the stage of jaundice development, absence of specific markers, complicating pre-surgical differential diagnostics of surgical group of diseases [5, 7].

In recent years awareness of anatomical peculiarities of a patient depending not only on sex but also age, constitution, individual

anatomical peculiarities of a person, has become of an important value, especially for the diagnostic direction of practical medicine in particular [1, 2].

A wide application of up-to-date mini-invasive diagnostic methods and visualization of organs such as ultrasound diagnostics (USD), computed tomography (CT), and magnetic-resonance imaging (MRI), opens new possibilities for the detection of individual lifetime anatomical norm of the healthy human body and pathology at the early stages of disease with ability to prevent it [9, 10, 11, 12].

Objective of our study was to determine the frequency of occurring morphological peculiarities of the gallbladder structure and its functional changes that can be risk factors promoting development of bile expelling structure pathology in healthy adult individuals of different sexes according to the findings of ultrasound examination of the HDA organs.

Materials and methods. To determine the sickness rate of gallbladder and bile ducts diseases 136 adult people were examined by means of the ultrasound apparatus «Radmir Ultima RU-928» including 60 (44,1%) men and 76 (55,9%) women.

The investigation was conducted by means of a convective sensor with the frequency band from 1 to 5 mHz ($\pm 0,5$ mHz) R60 mm. The study was conducted on the base of USD consulting room at Volyn Regional Infectious Hospital.

The individuals involved in the study were distributed according to their sex and age in the following way:

- 48% of the general number of those examined were men (37 individuals), including 27% of them (10 individuals) at the age of 36 years, and 73% (27 individuals) – older than 36;

- 52% of the general number of those examined were women (40 individuals), including 42,5% of women (17 individuals) aged under 36 years, and 57,5% (23 individuals) – older than 36 (Fig. 1).

The investigations were conducted with the purpose of screening within the frame of planned preventive mass-scale examinations or ultrasound diagnostics of the internal organs according to references not connected with pathology of the hepatic-biliary structures. Anamnesis of the examined patients did not contain any diseases of the liver, gallbladder and bile ducts.

Results. No pathological changes in the

examined structures that could be considered as diseases were found in 77 individuals (56%) (Fig. 2).

Although the examined patients did not complain of disorders from the side of the hepatic-biliary system, certain morphological peculiarities (flexion) and functional disorders (cholestasis) of the examined structures were found (Table 1). The following morphological changes were found among 37 examined men:

- flexion in the neck portion in 3 people (8,1%),
- flexion in the portion of the body – 1 person (2,7%),
- flexion in the portion of the fundus – 2 individuals (5,4%),
- flexion in the portion of the body and neck – 2 individuals (5,4%), (Fig. 3).

Similar changes were detected among the examined 40 women:

- flexion in the neck portion in 4 individuals (10%),(Fig. 4),
- flexion in the portion of the body – 1 person (2,5%),
- flexion in the portion of the fundus – 1 person (2,5%).

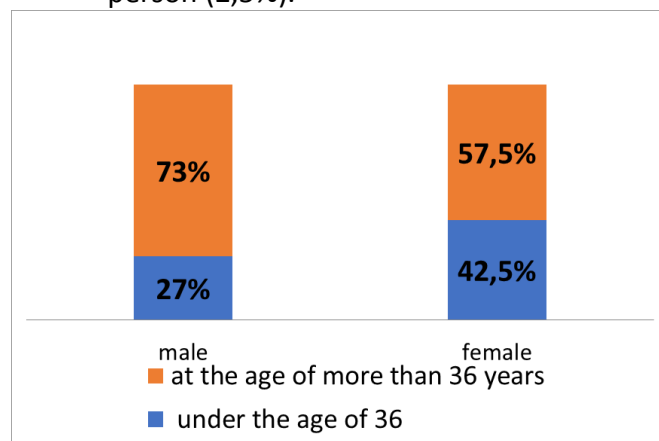


Fig. 1. Distribution of the examined people by sex and age.

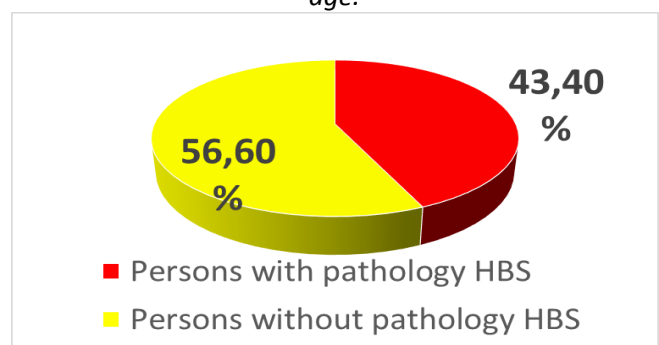


Fig. 2. Distribution of the examined adult individuals according to the frequency of detection of hepatic-biliary system (HBS) pathology.

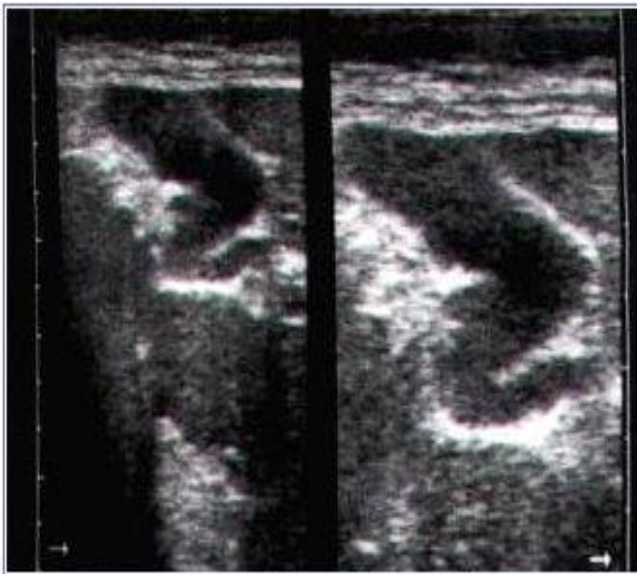


Fig. 3. Ultrasound image of the gallbladder with flexion in the portion of the neck and body.

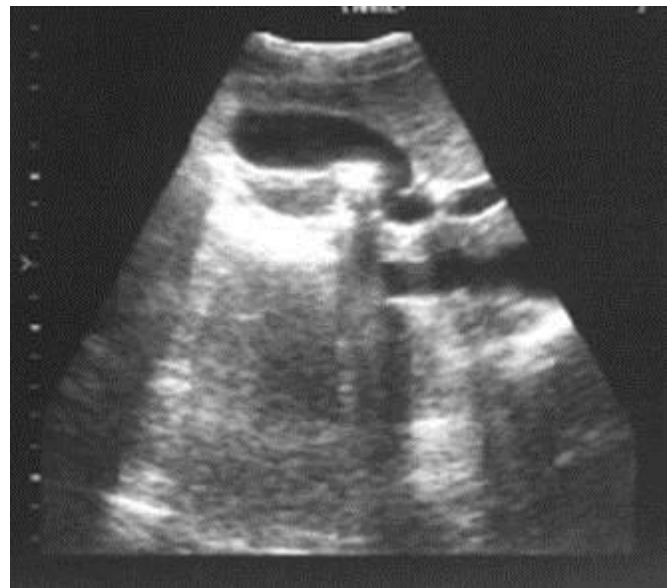


Fig.4 Ultrasound image of the gallbladder with flexion in the portion of the neck.

Therefore, among the group of randomized patients who do not complain of disorders from the side of the liver and bile ducts as well as diseases that could influence on the condition of the hepatic-biliary organs in anamnesis, the frequency of morphological peculiarities in the form of gallbladder flexion constitutes 18,2% from the general amount of the examined people including 21,6% of men and 15% of women among them.

Screening examination of the adult individuals detected functional changes in the examined area – cholestasis in particular, that was not clinically manifested. Asymptomatic cholestasis during examination was found in 16 people which constitutes 20,8% from general number of the

healthy examined people including 7 men (18,9% from all the examined men) and 9 women (22,5% from all the examined women) (Table 2).

Discussion of the results. Numerous sources of scientific literature are indicative of sickness rate increase concerning the organs of the hepatic-biliary system as well as increased possibilities of modern methods of their early diagnostics in individuals without clinical signs of disease [4, 6, 7]. Results of our studies evidenced rather high frequency of changes found in the examined structures that can be considered as diseases in 43,4% randomized adult individuals who underwent screening examinations or ultrasound diagnostics of the internal organs according to

Table 1.

Frequency of occurrence of gallbladder flexion of different localization in adult individuals of different sexes

Localization of flexion	Men				Women			
	Younger than 36		Older than 36		Younger than 36		Older than 36	
	10	100%	27	100%	17	100%	23	100%
Flexion in the neck	1	10	2	7,4	1	5,9	3	13
Flexion in the body			1	3,7			1	4,3
Flexion in the fundus			2	7,4			1	4,3
Flexion in the body and neck			2	7,4				

Table 2.

Frequency of occurrence of asymptomatic cholestasis in adult individuals of different sexes

Sex	Men				Women			
Age	Under 36		Older than 36		Under 36		Older than 36	
Number of examined people	10	100%	27	100%	17	100%	23	100%
Cholestasis	3	30	4	14,8	5	29,4	4	17,4

references not connected with pathology of the structures of the hepatic-biliary system. Ultrasound diagnostics was found to be able to detect morphological peculiarities in the form of flexion localized in different portions of the gallbladder and asymptomatic functional disorders in the form of cholestasis even when patients did not complain of disorders from the side of the liver and bile ducts.

Therefore, the results of the studies conducted enable to draw the following **conclusions**:

1. Screening ultrasound diagnostic examination enable to detect both morphological peculiarities and functional disorders of the gallbladder – cholestasis in particular, in adult patients who do not complain of disorders that were not clinically manifested.

2. Among the examined 77 healthy adult individuals including 37 men and 40 women gallbladder flexion was found in 18,2% from the general number of those being examined (21,6% of men and 15% of women). Examination detected asymptomatic cholestasis in 16 people which is 20,8% from general number of those healthy examined ones including 18,9% of men and 22,5% of women.

3. Detection of morphological peculiarities of the gallbladder structure and early diagnostics of cholestasis in individuals without complaints and clinical manifestation of pathology of HAD organs enable to improve the efficacy of preventive measures directed to maintenance of functional ability of the examined structures.

Prospects of further studies. High sickness rate of the diseases of the gallbladder and bile ducts is a foundation to conduct investigations with the purpose to find morphological peculiarities of the examined structures that can influence on their function. The search for new up-to-date method of early diagnostics of morphological and functional changes with the aim to improve the efficacy of preventive and therapeutic measures becomes especially important.

References:

1. Belik N.V. Vikovi ta henderni osoblyvosti ul'trazvukovykh parametriv pechinky ta selezinky u mis'kykh pidlitkiv. Visnyk morfolohiyi. 2002; 8 (2): 345-8.

2. Tran TT, Ahn J, Reau NS. Bolezny pecheny y beremennost': klynycheskye rekomendatsyy

Amerykanskoj kollehyi gastroenterologov. Zdorov'ya Ukrainy. Temat. nomer: Gastroenterolohiya. Hepatolohiya. Koloproktolohiya. 2016 veresnya; 3: 43-5. Hayda SM. Tendentsiyi poshyrenosti zhovchnokamyanoi khvoroby sered naselennya Ukrainy. Ukrayins'kyi medychnyy chasopys. 2011; 4: 112-3.

3. Zheliba MD, Zhuchenko O.P., Verba AV. Zastosuvannya ul'trazvukovoho doslidzhennya u diahnozytsi hostroyi zapal'noyi patolohiyi zovnishnikh zhovchovyvidnykh shlyakhiv ta yoho znachennya dlya vyboru likars'koyi polityky. Khirurhiya Ukrainy. 2009; 4: 51-4.

4. Lurin I.A., Zheliba MD, Slobodyanyk VP, Verba AV, Rahushyn D.A. Porivnyal'na efektyvnist' suchasnykh metodiv diahnozytyky zhovchnokamyanoi khvoroby ta yiyi uskladnen'. Ukrayins'kyi zhurnal maloynvazyvnoyi ta endoskopichnoyi khirurhiyi. 2009; 4: 40-2.

5. Perederiy NO. Medyko-sotsial'na problema zabolevaniya zhovchovyvidnykh shlyakhiv u khronobiologichnomu aspekti. Visnyk problem biolohiyi ta medytsyny. 2006; 1: 89-94.

6. Slobodyan OM, Akhtemiychuk YUT. Suchasni vidomosti pro topohrafiyu zhovchnoho mikhura ta yoho protoky. Klinichna anatomiya ta operatyvna khirurhiya. 2007; 6 (2): 91-4.

7. Shcherbynyna MB. Novoe v profilaktytsi, diahnozytsi ta likuvanni zhovchnokamennoyi khvoroby. Zdorov'ya Ukrainy. Temat. nomer: Gastroenterolohiya. Hepatolohiya. Koloproktolohiya. 2016 traven'; 2: 28-9.

8. Gameraddin M, Salih S, Suliman A, Yousef M. Diahoz hostroho kholetsystytu z vykorystanniam ul'trasonohrafiyi. J Dent Med Sci. 2013; 6 (6): 65-70.

9. van Renden A, Lameris V, van Es KH.V., van Khesevik KH.P., van Ramskorst B, De Ten Khou i in. Porivnyannya tochnosti ul'trazvuku ta komp'yuternoyi tomohrafiyi pry zahal'nykh diahnozakh, shcho sprychynayut' hostryy bil' u zhyvoti. Eur Radiol. 2011 r., 21 (7): 1535-45.

10. Brenner DJ, Hall EJ. Komp'yuterna tomohrafiya: zbil'shennya radiatsiynoho oprominennya. N Engl J Med. 2007; 357: 2277-84.

11. Khekimohlu K., Ustundaha I., Dusaketel A. MRSP proty ERCP pry otsintsi biliarnoyi patolohiyi: ohlyad potochnoyi literatury. J Dig Dig. 2008; 9 (3): 162-9.