

Paltov E.V.,
 Kryvko Yu.Ya.,
 Zhukovskiy V.S.,
 Fik V.B.,
 Vilkhova I.V.,
 Pankiv M.V.

Danylo Halytskyi Lviv National Medical University, Department of Normal Anatomy, 69, Pekarska str., Lviv, Ukraine

PATHOMORPHOLOGIC CHANGES IN THE RETINA LAYERS AT THE END OF THE FOURTH WEEK OF OPIOID EFFECT

Abstract. *the objective of the presented research is to conduct fundamental investigation concerning the issues of increasing processes of pathomorphologic changes in the retinal layers at the end of the fourth week of experimental opioid effect. The stated objective was achieved by means of application of histological visualization methods of the retinal layers. Histological specimens were prepared according to the common methods using staining agents: hematoxylin, eosin, azure and azan according to Handenhein's method. In future this information will enable to form pathomorphologic basis of the postmortem manifestation of the retinal layers exposed to four-week experimental opioid effect. It will provide an opportunity to form pathomorphologic substrate with further possible comparative characteristics of the retinal layers of a rat under the effect of opioid at different stages, early and late periods of correction.*

Key words: *fourth week, opioid, retina, rat.*

Introduction. The results of the study correspond to the plan of scientific investigations of Danylo Halytskyi Lviv National Medical University, and it is a part of the scientific-research topic of the Department of Normal Anatomy "Structural organization, angioarchitectonics, and anthropometric peculiarities of the organs during internal and external uterine periods of development under conditions of exo- and endopathogenic factors" (state registration number 0115U000041) during 2015 – 2019.

Introduction. The UN Program dealing with the control over drugs suggests that a considerable part of individuals who are illegally addicted to drugs in the world ranges from 3,3 to 4,1% of the whole population [1]. To Khubkhanberdina's opinion about 52 million in the world systematically use drugs – and it is 1 % of the global population [2]. A real number of individuals who abuse drugs cannot be exactly calculated due to latency of the pathology [3,4]. A few works are available that partially deal with certain aspects of ophthalmologic pathology in case of opioid effect [5 – 8]. It is the very case when ophthalmologists are the first to find inconsiderable signs of chronic

opioid effect and determine the symptoms of affliction of the visual organ structures. Facing the signs of opioid effect, specialists can be unprepared to identify and diagnose opioid effect due to the lack of systematized findings concerning morphological signs of opioid effect on the visual organ and changes in the retina layers in particular [9, 10].

Therefore, the study is considered to be topical both from the point of view of experimental pathomorphologic investigation and practical aspects.

Materials and methods. Material of the study was 15 mature outbred male rats with the body weight of 160-200 g, and 5,5 months of age. The animals were i/m injected with Nalbuphine every day once a day at the same period of time (10-11 a.m.) during 28 days. The initial dose of Nalbuphine was 0,212 mg/kg. Every following two weeks of the experiment the dose of the drug was gradually increasing within the range of a permissible therapeutic dose. From the 14th day to the end of the 28th day animals were administered to Nalbuphine in the dose of 0,225 mg/kg. Therefore, the model of chronic opioid effect was

created including introduction of an opioid narcotic analgesic to experimental animals in increasing doses [11].

The animals were divided into two groups. The 1st group of animals received Nalbuphine during 28 days with the following taking the material for examination (at the end of the 4th week of experimental opioid effect); the 2nd control group received i/m injections of physiological solution during 28 days at the same period of time (10-11 a.m.).

All the animals were kept in vivarium and the work concerning their care, marking and all the other manipulations were conducted according to the regulations of “The European Convention for the Protection of Vertebrate Animals used for Experimental and other Scientific Purposes” [Strasburg, 1985], “Ethical Principles and Guidelines for Experiments on Animals”, approved by the First National Congress on Bioethics [Kyiv, 2001]; the Law of Ukraine № 3447 – IV “On protection of animals against cruelty”. The Bioethics Expert Board of Danylo Halytskyi Lviv National Medical University determined that conducted scientific studies correspond to ethical requirements according to the Order of the Ministry of Health of Ukraine № 231 dated 01. 11. 2000 (minutes № 10 dated 26.12. 2011; minutes №2 dated 20.02.2012).

Before the material for biopsy was taken, animals were put to sleep by means of the intraperitoneal introduction of Thiopental (in the dose of 25 mg/kg). The following material for the microstructural examination was used: eyeballs of rats obtained by means of postmortem enucleation followed by further maintenance of topographic ratio of the eye retina making histological sections 5-7 mcm thick. Histological specimens were prepared according to the common methods using staining agents hematoxylin, eosin, azure and azan according to Handenhein’s method [12]. Microscopic examinations and photographing of samples were conducted by means of the microscope MBI-1 and digital camera Nikon D 3100.

Results. Microscopic examination of the structural organization of the retina layers in rats at the end of the fourth weeks of the experiment determined more intensive proliferation of the pigment epithelium (I). In the epithelial cells

located in the area of the retina the cytoplasm along the toothed line is cleared with formation of vacuoles, and swollen a little. The basal membrane is markedly swollen, heterogeneous, integral and loose along its bigger space. The collagen fibers of the basal membrane are basophilic and loose; the basic substance is cleared and contains cavities. The nuclei of the photosensory cells transfer to the photosensory layer (II). Internal areas of photoreceptors are stained more intensively. The structure of the external boundary layer (III) at this stage of the experiment among the control and experimental groups of animals is similar. In the external nuclear layer (IV) the nuclei of photosensory cells are located in a loose way, and space between them is widened. The number of nuclei of an irregular shape and pyknosis signs increases (Figure 1). In the area of the visual nerve disk the external nuclear layer is thinner, the space between nuclei is bigger, the number of nuclear lines is 3-6; the same number of nuclei is found in the areas of the retina along the toothed line (3 – 6).

The outline of the external retinal layer (V) is not clear, since microcysts and cleared cells of the internal nuclear layer protrude into the external retinal layer (Figure 2). Clear spaces between capillaries increase on the border of the internal nuclear and external retinal layers.

In the internal nuclear layer (VI) many spaces between nuclei and the signs of pericellular

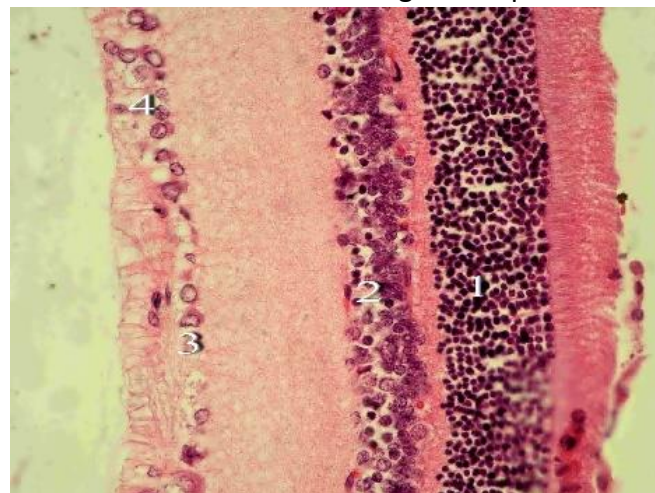


Figure 1. Retina of a rat four weeks after opioid introduction. Staining with hematoxylin and eosin. Magnification: x 400. 1– pyknotic nuclei in the external nuclear layer; 2– dilation of capillaries in the internal nuclear layer; 3– pericellular swellings of ganglionic cells; 4– microcystic cavities in the nervous-fibrous layer.

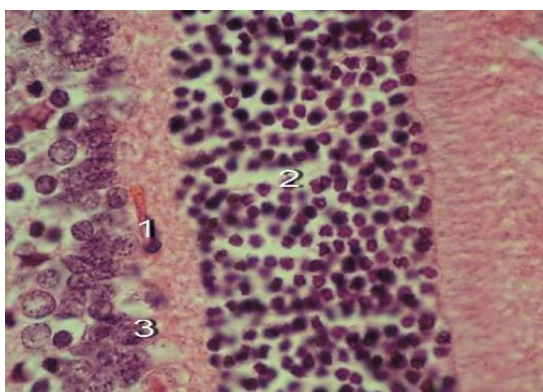


Fig. 2. Retina of a rat four weeks after opioid introduction. Staining with azan. Magnification: x 400. 1– dilation of the capillary clear spaces on the border of the internal nuclear and external retinal layers; 2– widening of the intervals between the nuclei of photosensory cells with the signs of karyopyknosis in some of them; 3– protrusion of the microcyst of the internal nuclear layer in the external retinal layer.

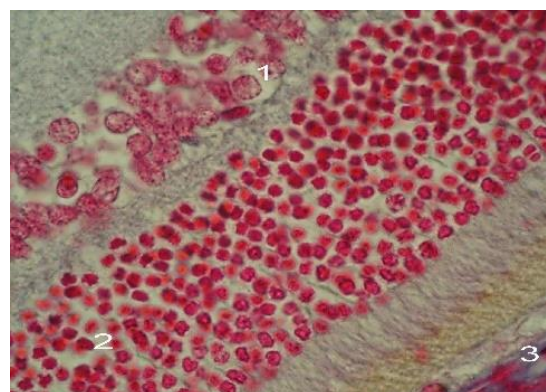


Fig. 4. Retina of a rat four weeks after opioid introduction. Staining with azan. Magnification: x 1000. 1– pyknosis and pericellular swelling in the internal nuclear layer; 2– enlargement of the distance between the nuclei in the external nuclear layer; 3– vacuolization of the pigment epithelium.

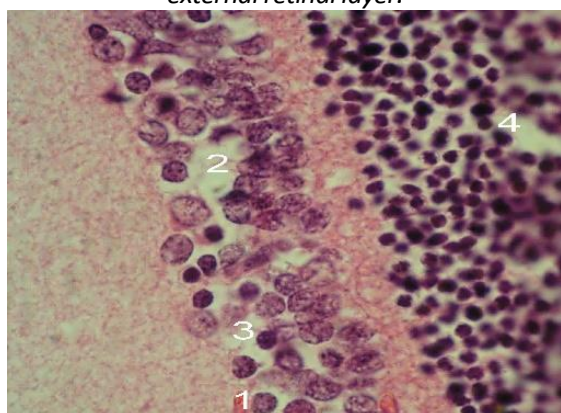


Fig. 3. Retina of a rat four weeks after opioid introduction. Staining with azan. Magnification 6 x 1000. 1– dilation of the capillaries located on the external and internal borders of the internal nuclear layer; 2– pericellular swellings in the internal nuclear layer; 3– karyopyknosis and reduced number of cells in the internal nuclear layer; 4– enlargement of the distance between the nuclei in the external nuclear layer.

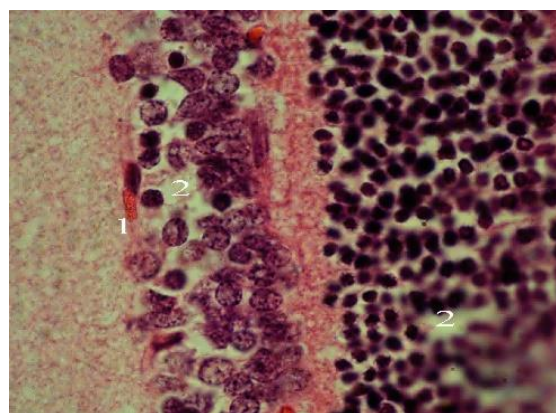


Fig. 5. Retina of a rat four weeks after opioid introduction. Staining with azan. Magnification: x 1000. 1– dilation of capillaries in the internal nuclear layer; 2– enlargement of the distance between the nuclei in the external nuclear and internal nuclear layers.

swelling are found (Figures 3 and 4). The capillaries located on the internal and external border of the internal nuclear layer have dilated spaces overfilled with blood (Figure 5).

In certain areas swelling of the internal retinal layer (VII) is found (Figure 6).

In the ganglionic layer (VIII) certain nuclei with cleared center are found, their chromatin is located close to the nuclear membrane. The nuclei of certain ganglionic cells are pyknotic, and others are in the condition of karyorrhexis. The central part of nuclei of certain ganglionic cells is cleared with the signs of pyknosis, some of them are in the condition of karyorrhexis. Cleared areas

(pericellular swelling) are visualized around ganglionic cells. Sometimes the retinal areas are found where ganglionic cells are located at considerable distances one from another. Certain capillaries located on the border of the ganglionic layer and the layer of nerve fibers have enlarged cleared spaces overfilled with blood. The capillary endothelium is a little thickened, swollen, and proliferation of the endothelial cells is found. The wall of the detected arterioles is irregularly thickened and swollen. The cytoplasm of the endothelial cells is irregularly stained and granular. The nervous-fibrous layer (IX) in certain areas contains microcysts bordering on and sometimes penetrating into the ganglionic layer (Figure 7). The lumens of vessels localized in the thickness of the nerve fibers layer are overfilled

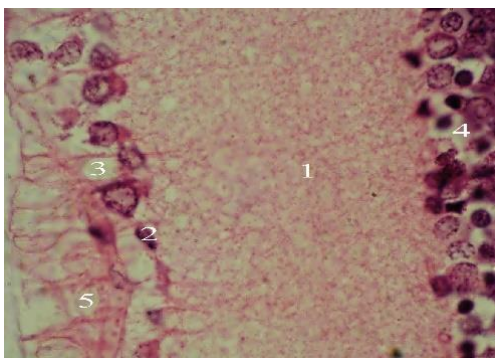


Figure 6. Retina of a rat four weeks after opioid introduction. Staining with azan. Magnification: x 1000. 1 – swelling of the internal retinal layer; 2 – necrotic changes of ganglionic cells; 3 – pericellular swellings of ganglionic cells; 4 – pericellular swellings of cells in the internal nuclear layer; 5 – microcystic cavities in the nervous-fibrous layer.

with erythrocytes, their endothelium is swollen, and their wall is irregularly thickened, swollen and winding. The internal bordering layer (X) is without pathologic changes.

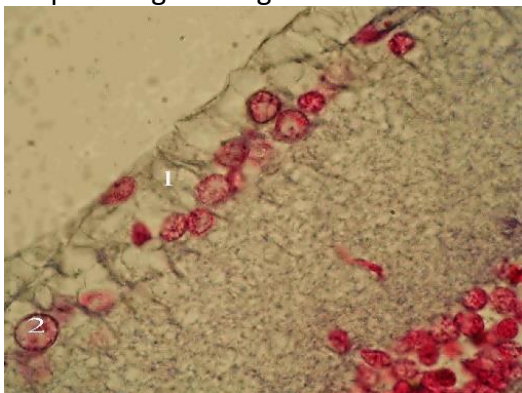


Figure 7. Retina of a rat four weeks after opioid introduction. Staining with azan. Magnification: x 1000. 1 – microcystic cavities in the nervous-fibrous layer; 2 – clearing the nuclear center of the ganglionic cell.

Conclusion: the end of the fourth week of opioid effect is characterized by appearance of single necrotic changes in nerve cells in the thickness of nuclear layers, and maintenance and intensification of signs of the intravascular, vascular and extravascular reconstruction (hyperemia, stasis, perivascular and pericellular swellings) in the internal retinal layers.

Prospects of further studies.

Pathomorphologic signs in the retinal layer in the course of experimental opioid effect at the end of the fourth week can form pathomorphologic basis with the purpose to study the signs of opioid angio- and neuroretinopathy in the experiment. The results obtained can be further used to perform comparative characteristics concerning the dynamics of increasing pathomorphologic changes in the retinal layers in case of short-term

and long-term action of opioid small doses.

References:

1. Gamaleya NB, Ul'yanova NLI, Khotovitskiy AV. Pokazateli kletochnogo i gumoral'nogo immuniteta u bol'nykh geroinovoy narkomaniyey i ikh korektsiya immunomodulyatorom taktivinom. *Voprosy narkologii*. 2001;(4):50-54.
2. Khubkhanberdina AS. Strukturno – dinamicheskiye osobennosti opiynoy narkomanii pri sochetannoy psikhicheskoy patologii. *Narkologiya*. 2004;(5):37-41.
3. Dragan GI. Narkomaniya sredi nesovershennoletnikh v Rossii: situatsiya, tendentsiya, protivodeystviye. *Voprosy narkologii*. 1997;(2):76-84.
4. Pyatnitskaya IN. Narkomaniya kak sotsial'naya i obshchemeditsinskaya problema. *Rossiyskiy meditsinskiy zhurnal*. 1996;(4):5-10.
5. Yakimiv NYa. Toksichne urazhennya zorovikh nerviv vnaslidok trivalogo priyomu levomitsetinu na tli narkotichnoy zalezhnosti vid kodterpinu. *Oftal'mol zhurnal*. 2012;(3):43-5.
6. Yakimiv NYa., Krivko Yu. Mikrostrukturna kharakteristika rayduzhno-rogivkovogo kuta ochnogo yabluka shchuriv pri opioidnomu vplivi. *Svit meditsini ta biologii*. 2013;(4):120-4.
7. Yakimiv NYa. Ul'trastrukturna kharakteristika struktur rayduzhno-rogivkovogo kuta ochnogo yabluka shchuriv na 35-u ta 42-u dobu opioidnogo vplivu. *Svit meditsini ta biologii*. 2014;(2):185-8.
8. Yakimiv NYa. Ul'trastrukturna kharakteristika struktur rayduzhno-rogivkovogo kuta ochnogo yabluka shchuriv na 7-u, 14-u, 21-u, 28-u dobu opioidnogo vplivu. *Ukrains'kiy morfologichny al'manakh*. 2014;(2):28-31.
9. Paltov Y, Kryvko Y, Fik V, Vilkhova I, Ivasivka Kh, Pankiv M, Voitsenko K. *Deutscher Wissenschaftsherold. German Science Herald*. 2016;(2):30-3.
10. Paltov Y, Kryvko Y, Fik V, Vilkhova I, Ivasivka K, Pankiv M, Voitsenko K. *Pathomorphological manifestations in the retina layers during one - week of opioid analgesic exposure. Natural Science Readings abstracts booc (May 19 – 22, 2016, Bratislava)*. 25-7 p.
11. Pal'tov EV, Fik VB, Vil'khova IV, Onis'ko RM, Fit'kalo OS, Krivko YuYa. *Sposib modelyuvannya khronichnogo opioidnogo vplivu. Patent №76565. L'vivs'kiy natsional'niy medichniy universitet imeni Danila Galits'kogo*.
12. Romeys B. *Mikroskopicheskaya tekhnika. – M.: Meditsina*. 1953.– p. 71 – 72.