

Dear subscribers!

This issue of our magazine is devoted to cooperation of our editorial board with Ukrainian medical scientists.

We present you the results of their researches.

UDC 611.835.8:618.29

**Khmara T.V.,
Komar T.V.**

Higher State Educational Institution of Ukraine "Bukovinian State Medical University", N.H. Turkevych Department of human anatomy, Chernivtsi, Ukraine, khmara_tv@mail.ru

INDIVIDUAL ANATOMICAL VARIABILITY IN THE INNERVATION OF THIGH AND CALF MUSCLES IN HUMAN FETUSES

Abstract. *The study of features of the topography of the sciatic nerve and its branches has been conducted on 7 human fetuses aged 6 months. We found a high division of the sciatic nerve into the tibial and common peroneal nerves in two fetuses. We described the involvement of the sciatic nerve in the innervation of the quadratus muscle of thigh, piriform and gluteus maximus muscles, as well as the part of the tibial nerve in the innervation of the long head of the biceps femoris, semitendinosus and semimembranosus muscles. We established the individual anatomical variability in the distribution of intramuscular nerves in the posterior group of thigh muscles, back, lateral and anterior groups of calf muscles.*

Key words: *sciatic nerve, tibial nerve, superficial peroneal nerve, deep peroneal nerve, fetus, human.*

Introduction. The symptoms of compression of the sciatic nerve in the infrapiriform foramen develop on the basis of its topographical and anatomical relationship with the surrounding structures. Severe lesions of the sciatic nerve are usually accompanied by severe paresis or paralysis of the back lower limb muscles [1-2]. Establishing accurate data about the features of the topography of the sciatic nerve and its branches, as well as the awareness of the general laws of the intramuscular nerve distribution in each muscle of the thigh and calf in different periods of human ontogenesis is necessary to carry out diagnostic procedures and surgical intervention [3].

Objective: to establish the features of the intramuscular distribution of nerves in the muscles of the thigh and calf in fetuses aged 6 months.

Materials and methods. The study of topographic and anatomical features of innervation of the lower limb muscles was performed on 7 human fetuses with 186,0-230,0 mm of crown-rump length (CRL) using the

methods of fine preparation, vascular injection and morphometry.

Results and discussion. While studying the features of the topography and formation of the terminal branches of the sciatic nerve in six-month-old fetuses it was established that the right sciatic nerve was divided into the tibial and common peroneal nerves on the level of the back lower third of the thigh (42.85% of cases) or the upper corner of the popliteal fossa (42.85 %); one case (14.3%) showed a high division of the sciatic nerve into its terminal branches. We found the following levels while studying the bifurcation of the left sciatic nerve: between the middle and lower third of the back of the thigh (28.6%), on the rear surface of the lower third of the thigh (42.8%), upper corner of the popliteal fossa (14.3%), a high division of the sciatic nerve was found in one fetus (14.3%).

We found high branching of the left sciatic nerve trunk into the tibial and common peroneal nerves, namely 11.0 mm below the infrapiriform foramen in the fetus with 193,0 mm of CRL. The

extrapelvic part of the sciatic nerve is 14,0 mm long, the tibial nerve is 51,0 mm and the common peroneal nerve is 38.0 mm. The sciatic nerve gives muscular branches that innervate the piriform muscle, inferomedian part of the gluteus maximus, the quadratus muscle of thigh, the proximal part of the semitendinosus and semimembranosus muscles, as well as the upper part of the long head of the biceps muscle of thigh. After branching from the sciatic nerve, the tibial nerve goes to the popliteal fossa along the posteromedial thigh, innervating the muscles of the posterior group of the thigh.

The right sciatic nerve of a fetus with 200.0 mm of CRL leaves the pelvic cavity through the infrapiriform foramen along with the posterior cutaneous nerve of thigh, two inferior gluteal nerves, inferior gluteal vessels and sexual neurovascular bundle. The sciatic nerve runs 5.6 mm laterally to the ischial tuberosity, lying under the gluteus maximus muscle. The right sciatic nerve in the gluteal region is 9.0 mm long. At a distance of 7.0 mm below the infrapiriform foramen the sciatic nerve branches into the tibial and common peroneal nerves. The tibial nerve is 42,0 mm long from the place where it branches from the sciatic nerve and to the popliteal fossa and its total length is 87.0 mm. The common peroneal nerve is 41.0 mm long and it is located laterally to the tibial nerve. The tibial nerve branches into 4 muscular branches that approach the long head of the biceps femoris muscle from its front surface, one branch from the common peroneal nerve goes to its short head. Most of intramuscular nerve trunks in the thickness of the long and short heads of the biceps femoris go downwards. However, none of the nerve trunks penetrates into the thickness of the neighboring head. Two muscular branches which are 4.0 mm and 4.4 mm long go from the tibial nerve to the semimembranosus muscle at an acute angle and the gate for their entrance is located along the outer edge of the upper third of the muscle (Fig. 1).

In the depth of the muscle belly of the semimembranosus muscle the direction of nerve trunks coincides with that of the main arterial trunks. Three muscular branches, whose entrance lies in the areas of the proximal and

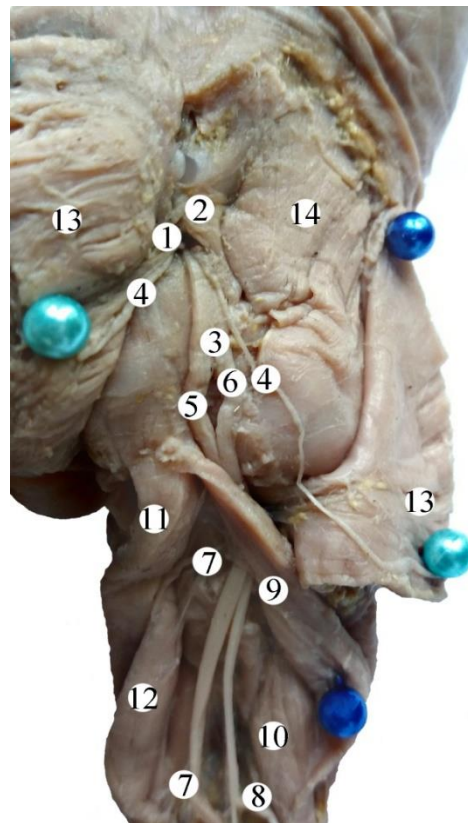


Fig. 1. Right gluteal region of a fetus with 200,0 mm of CRL. Rear view. Gross specimen. Magn. 2,3^x: 1 – infrapiriform foramen; 2 – piriform muscle; 3 – sciatic nerve; 4 – inferior gluteal nerves; 5 – tibial nerve; 6 – common peroneal nerve; 7 – muscular branches from the tibial nerve; 8 – a muscular branch from the common peroneal nerve; 9 – long head of the biceps femoris muscle; 10 – short head of the biceps femoris muscle; 11 – semitendinosus muscle; 12 – semimembranosus muscle; 13 – gluteus maximus muscle; 14 – gluteus medius muscle.

distal parts of the muscle, go at an acute angle from the tibial nerve to the semitendinosus muscle.

The common peroneal nerve 3.5 mm above the lateral epicondyle of the femur divides into superficial and deep fibular nerves. The superficial fibular nerve passes under the long peroneal muscle, then passes to the medial surface of the short peroneal muscle and in the lower third of the leg branches into the dorsal cutaneous nerves of the foot. The entrance for two branches in the long peroneal muscle, which extend at an acute angle from the superficial tibial nerve, is located in the upper third of the muscle belly 4.0-5.0 mm below the fibular bone head (Fig. 2). Two branches (anterior and posterior ones) go into the depth of the short tibial muscle on the side of the

respective surfaces of the upper third of the muscle belly, at the level of the pass of the proximal tendon into the muscle belly.

The deep fibular nerve pierces the thickness of the initial parts of the long peroneal muscle and the extensor digitorum longus, and runs from the lateral side of the anterior tibial vessels. It should be noted that the deep fibular nerve in the upper portion of the calf is located between the extensor digitorum longus and the anterior tibial muscle whereas in the middle and lower portions it lies between the anterior tibial muscle and long radial extensor muscle of foot innervating these muscles.

Three branches enter the upper third of the muscle belly of the extensor hallucis longus

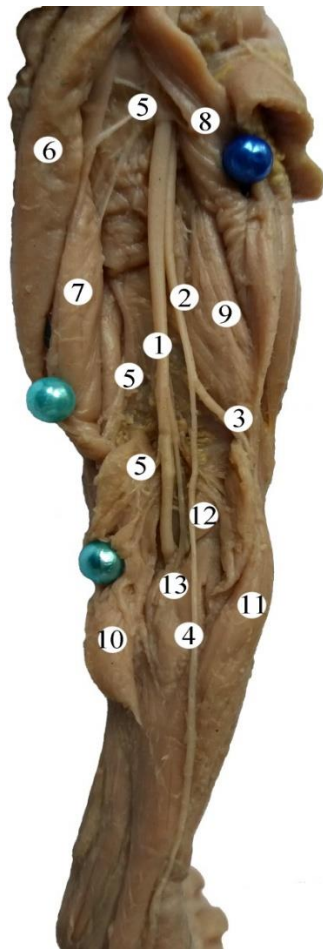


Fig. 2. Nerves of the back part of the right lower limb in a fetus with 200,0 mm of CRL. Gross specimen. Magn. 1,8^x: 1 – tibial nerve; 2 – common peroneal nerve; 3 superficial peroneal nerve; 4 – lateral cutaneous nerve of calf; 5 – muscular branches from the tibial nerve; 6 – semitendinous muscle; 7 – semimembranous muscle; 8 – long head of the biceps femoris muscle; 9 – short head of the biceps femoris muscle; 10 – medial head of the gastrocnemius; 11 – long peroneal muscle.

muscle at an acute angle, dividing by a mixed type; two branches from the deep peroneal nerve penetrate into the upper and middle third of the muscle belly of the anterior tibial muscle at an acute angle. Two nerve trunks in the anterior tibial muscle go downwards: they branch by the main type. In this type the branches of the anterior tibial artery in the muscle of the same name have the transverse direction. In the initial section of the anterior tibial muscle nerve trunks are located in front of the arteries, and then they change direction, the arteries intersect with the nerves and lie in front of them. The entrance for the nerve trunk from the deep peroneal nerve into the extensor hallucis longus is placed in the upper third of its muscle belly. Then the nerve trunk in the thickness of the muscle belly of the extensor hallucis longus, in turn, divides into the anterior and posterior branches, which pass in front of the arteries and cross them. The common peroneal nerve also gives the lateral cutaneous nerve of calf, being 51.0 mm long, which branches in the skin of the lateral surface of the calf.

In the popliteal fossa the tibial nerve is located superficially and laterally to the popliteal vein, which, in turn, passes laterally and posteriorly to the popliteal artery. The tibial nerve gives four short, from 1.8 mm to 2.4 mm long, muscular branches at an acute angle to the popliteal muscle. The places of entrance for the latter ones are located at the border between the middle and the lower thirds of the muscle belly, with three branches going to the middle third of the popliteal muscle belly. At the level of the lower angle of the popliteal fossa the tibial nerve divides into two branches: the anterior and posterior ones. The anterior branch of the tibial nerve spreads in the thickness of the lateral and medial parts of the soleus muscle, and the posterior branch of the tibial nerve penetrates into the thickness of the back surface of the muscle.

The entrance for the muscular branches of the tibial nerve in the medial head of the gastrocnemius muscle is located 4.0 mm above the entrance for nerves of the lateral head. The direction of intramuscular nerve trunks does not coincide with the direction of the muscle bundles. It should be noted that the main nerve trunks divide by scatter type, while the

branches, leaving these trunks divide by main type. It should be emphasized that there are much more intramuscular nerve connections in the lateral head of the gastrocnemius muscle than in the medial head of the muscle. From the popliteal fossa the tibial nerve goes to the cruropopliteal canal whose foramen is limited anteriorly by the popliteal muscle and posteriorly by the poorly expressed tendinous arch of the soleus muscle. In the cruropopliteal canal the tibial nerve is accompanied by the posterior tibial artery and veins. Muscular branches of the tibial nerve enter the thickness of the posterior tibial muscle from its dorsal surface in the upper third of the muscle belly. Direction of the intramuscular nerve trunks does not coincide with that of the intramuscular arteries. The tibial nerve gives two branches, going at an acute angle to the flexor pollicis longus muscle from the rear surface of the muscle belly. The entrance for the branches that go from the tibial nerve to the flexor hallucis longus muscle, is located in the upper third of the muscle belly. However, in the thickness of the muscle belly the direction of the intramuscular nerves does not coincide with that of the intramuscular arteries. Then, the tibial nerve goes between the lateral edge of the long flexor pollicis longus muscle and the medial edge of the flexor hallucis longus muscle, reaches the back surface of the medial malleolus, where it divides into two terminal branches: the medial and lateral plantar nerves. The medial plantar nerve is located in the medial plantar sulcus along with the homonymous artery supplying the flexor digitorum brevis and the hallucis longus muscles, with the exception of the muscle which brings the big toe and the lateral part of the flexor hallucis brevis muscle, which are innervated by the lateral plantar nerve. Terminal branches of the medial plantar nerve are the proper plantar digital nerves. The lateral plantar nerve, which is accompanied by the homonymous artery and innervates the muscles of the little toe of the foot, the plantar quadratus muscle and three plantar interossei muscles runs in the lateral plantar sulcus.

Conclusions: 1. The sciatic nerve and its branches are a source of innervation of the back thigh muscle group and the muscles of the back,

front and lateral groups of the calf. Muscular branches of the sciatic nerve are involved in the innervation of the muscles of the quadratus muscle of thigh, piriform and gluteus maximus muscles. In case of a high division of the sciatic nerve into the terminal branches, the muscles of the back group of thigh are innervated by the branches of the tibial and common peroneal nerves.

2. The nerves enter the thickness of the majority of the muscles of thigh and calf at an acute angle to the long axis of the muscle. The entrances for the nerves are more often located in the upper third of the muscle belly, sometimes in its middle third and, as an exception (popliteal muscle), in the lower third. The entrances for the nerves may be located both on the anterior and the posterior part of the muscle belly. In some muscles (soleus, peroneal) the entrances for nerves are located on two opposite sides of the muscle. In the semitendinosus muscle, preserving merism in its structure, separateness in the innervation is expressed.

3. In the depth of thigh and lower leg muscles the nerves are distributed unevenly. We can distinguish between loose, main and mixed forms of branching in the picture of intramuscular nerve distribution. The direction of intramuscular nerves and type of their branching can be different in the same muscle.

Prospects of further research. The study of individual anatomical variability of the distribution of the nerves and the arteries in the thigh and calf muscles in fetuses of different age is of interest.

References:

1. Ахмедова Г.М. Подгруппевидная седалищная нейропатия: клинические варианты и алгоритм терапии / Г.М. Ахмедова, Т.В. Зимакова // Практическая медицина. – 2012. – № 57. – С. 129-131.
2. Макаров А.И. Анатомия седалищного нерва и варианты ветвления / А.И. Макаров, Н.Ю. Модянов // Бюллетень северного государственного медицинского университета. – 2013. – № 1. – С. 104-105.
3. Vasilchishina A.V. Opzioni topografia entro nervo sciatico zona gluteo nel periodo perinatale di ontogenesi umana / A.V. Vasilchishina, T.V. Khmara // Italian Science Review. – 2016. – Issue 1 (34). – PP. 134-137.